Review

trd Tuberculosis & Respiratory Diseases

Korean Clinical Practice Guidelines for Interstitial Lung Disease: Part 2. Idiopathic Pulmonary Fibrosis

https://doi.org/10.4046/trd.2026.0097
ISSN: 1738-3536(Print)/
2005-6184(Online)
Tuberc Respir Dis 2026;89:435-452

Hye Sook Choi[1], Hee-Young Yoon[2], So Young Park[3], Jongmin Lee[4], Ji Young Kang[5], Jun Yeun Cho[6], Sung Soo Jung[7], Won Il Choi[8] and on Behalf of the Korean Interstitial Lung Disease Study Group

[1]Department of Internal Medicine, Kyung Hee University Medical Center, Seoul, [2]Division of Pulmonary and Critical Care Medicine, Department of Internal Medicine, Soonchunhyang University Seoul Hospital, Seoul, [3]Division of Pulmonary, Allergy and Critical Care Medicine, Department of Internal Medicine, Kangdong Sacred Heart Hospital, College of Medicine, Hallym University, Seoul, [4]Division of Pulmonary and Critical Care Medicine, Department of Internal Medicine, Seoul St. Mary's Hospital, College of Medicine, The Catholic University of Korea, Seoul, [5]Department of Internal Medicine, Jeju National University Hospital, Jeju, [6]Division of Pulmonary and Critical Care Medicine, Department of Internal Medicine, Chungbuk National University Hospital, Chungbuk National University College of Medicine, Cheongju, [7]Department of Internal Medicine, Chungnam National University Hospital, Daejeon, [8]Department of Internal Medicine, Myongji Hospital, Hanyang University College of Medicine, Goyang, Republic of Korea

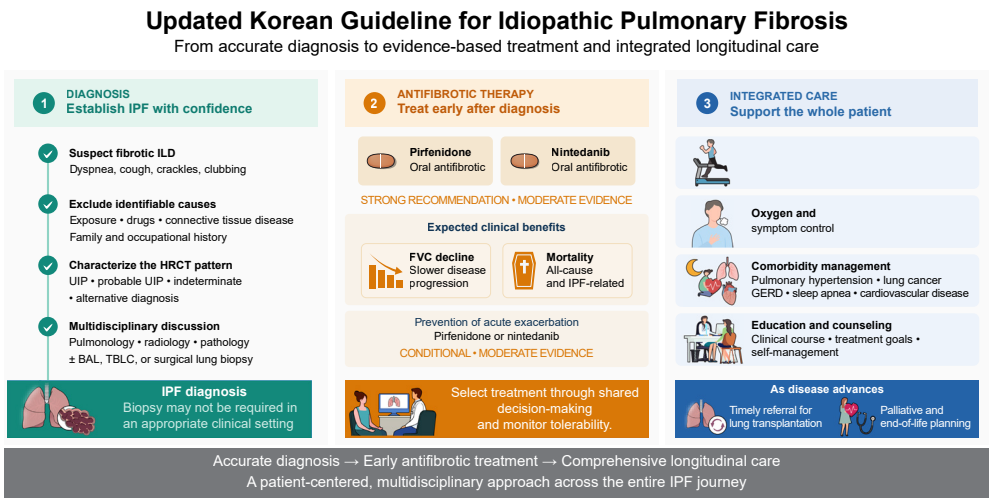

Abstract

Idiopathic pulmonary fibrosis (IPF) is a chronic, progressive, fibrosing interstitial pneumonia marked by declining lung function, severe dyspnea, and a poor prognosis. Antifibrotic agents have improved outcomes in patients with IPF, but diagnosing the disease, monitoring its course, and managing it over the long term remain challenging. Since the publication of the first Korean clinical practice guideline for interstitial lung disease in 2018, research has advanced substantially and has reshaped the clinical management of IPF. This updated guideline draws on evidence published over the past 5 years and covers the epidemiology, pathogenesis, risk factors, clinical manifestations, diagnosis, treatment, comorbidities, prognosis, and acute exacerbations of IPF. Expert consensus was also used to formulate key clinical questions, and systematic reviews and meta-analyses were then performed to reassess how antifibrotic agents affect lung function decline, mortality, and acute exacerbations in patients with IPF. This guideline

Check for updates

Copyright © 2026 The Korean Academy of Tuberculosis and Respiratory Diseases

Address for correspondence
Won Il Choi
Department of Internal Medicine, Myongji Hospital, Hanyang University College of Medicine, 55 Hwasu-ro 14beon-gil, Deokyang-gu, Goyang 10475, Republic of Korea
Phone 82-31-810-5432
Fax 82-31-969-0500
E-mail wichoi7572@hanyang.ac.kr

Received May 9, 2026
Revised Jul. 3, 2026
Accepted Aug. 24, 2026
Published online Aug. 26, 2026

It is identical to the Creative Commons Attribution Non-Commercial License (http://creativecommons.org/licenses/by-nc/4.0/).

aims to standardize the clinical management of IPF, improve diagnostic accuracy, and encourage the appropriate use of available treatments. It is intended for physicians, other healthcare professionals who care for patients with IPF, and healthcare policymakers in Korea.

Keywords: Idiopathic Pulmonary Fibrosis; Diagnosis; Management; Acute Exacerbation; Korea

Introduction

Idiopathic pulmonary fibrosis (IPF) is the most common form of idiopathic interstitial pneumonia (IIP). Progressive pulmonary fibrosis gradually reduces lung function and causes exertional dyspnea, and the disease predominantly affects older men and carries a poor prognosis. IPF remains a major clinical challenge because of its progressive course, difficulty in early diagnosis, and limited therapeutic options[1].

In 2000, the American Thoracic Society (ATS) and the European Respiratory Society (ERS) issued the first consensus statement on the diagnosis and treatment of IPF, which laid the foundation for standardized care[2]. The ATS and ERS have since worked with the Japanese Respiratory Society (JRS) and the Latin American Thoracic Society (ALAT) to develop successive clinical practice guidelines for diagnosing and managing IPF.

In Korea, the Korean Academy of Tuberculosis and Respiratory Diseases (KATRD) published the first clinical practice guideline for interstitial lung disease (ILD) in 2018 through its ILD Research Group[3]. That guideline rested on a systematic literature review and meta-analysis of studies that appeared after the 2011 ATS/ERS/JRS/ALAT guidelines[4], and an English version followed in 2019 to reach an international readership[5]. Meanwhile, the ATS, ERS, JRS, and ALAT revised the diagnostic criteria for IPF in 2018[6] and revised them again in 2022 to incorporate emerging evidence[7].

In Korea, evidence accumulated since the 2018 guidelines, together with evolving diagnostic approaches, made an update necessary. The first revised edition was therefore published in 2023 to provide accurate and current recommendations for diagnosing IPF and to support individualized treatment decisions that reflect patient values and preferences. It revised the diagnostic approach to IPF and added sections on nonpharmacologic management and IPF-associated comorbidities. The present English edition covers the updated content on epidemiology, diagnosis, treatment, comorbidities, acute exacerbations, and lung transplantation.

This guideline is intended primarily to help clinicians make evidence-based decisions when diagnosing, treating, and monitoring patients with confirmed or suspected IPF. It also offers recommendations for assessing long-term prognosis.

Building on the 2018 edition, the revised IPF section of the ILD clinical practice guideline pursues two goals:

(1) To incorporate the clinical research findings that have accumulated since the 2018 edition was published.

(2) To develop consensus-based recommendations through multidisciplinary collaboration, drawing on input from the Korean Society of Radiology and the Korean Society of Pathologists.

This clinical practice guideline was developed through a systematic process (Supplementary Materials and Methods, Supplementary Tables S1-5, and Supplementary Figures S1-9)[8-10].

Epidemiology

IPF is the most common subtype of the IIPs, a group of ILDs with no identifiable cause. In a Korean study of 2,186 patients given a diagnosis of IIP between 2003 and 2007, 77.1% had IPF[11], and a Western study similarly classified 68% of IIP cases as IPF[12].

In Korea, the annual incidence of IPF was 1.84 per 100,000 individuals among cases diagnosed between 1992 and 2010[13]. Studies from Taiwan and Japan reported annual incidences of 1.6 and 2.23 per 100,000 individuals and prevalences of 6.4 and 10.0 per 100,000 individuals, respectively[14,15]. After the international diagnostic guideline was revised in 2011[4], Korean studies reported a higher annual incidence of 12.9–13.1 per 100,000 individuals and a prevalence of 35.2–38.9 per 100,000 individuals[16,17].

Studies from the United States[18] and Canada[19] reported annual incidences of 17.4 and 25.8 per 100,000 individuals and prevalences of 63 and 78.4 per 100,000 individuals, respectively. Both the incidence and the

prevalence of IPF rise with age and are higher in men[16,20-22]. In a nationwide Korean cohort, the 1,345 patients given a diagnosis of IPF in 2018 had a mean age of 68.8 years, and 76% were men[23]. The Australian IPF Registry likewise reported a mean age of 71.9 years, with men accounting for 69% of participants[24]. Participants in international multicenter clinical trials have also been 65 years of age or older on average[25,26].

Recent studies have linked IPF to other chronic diseases. In one retrospective study, 88% of patients with IPF had at least one comorbidity, and cardiovascular disease and lung cancer influenced mortality most strongly[27]. Meta-analyses have identified IPF as a significant risk factor for lung cancer[28], particularly peripheral tumors, of which squamous cell carcinoma is the most common histologic type[29,30].

Reported prevalences of chronic obstructive pulmonary disease (COPD) among patients with IPF vary widely, from 6% to 67%[31]. Approximately 8% of cases present as combined pulmonary fibrosis and emphysema (CPFE), which differs from typical IPF in that lung volumes are preserved while diffusion capacity is reduced and pulmonary hypertension (PH), severe dyspnea, and hypoxemia are present[32].

Gastroesophageal reflux disease (GERD) has also been associated with IPF, although reported prevalences vary across studies[33]. Obstructive sleep apnea is another notable comorbidity; one Korean study reported

Table 1. High-resolution computed tomography patterns in idiopathic pulmonary fibrosis[7]

	HRCT pattern			
	UIP pattern	Probable UIP	Indeterminate for UIP	Alternative diagnosis
Distribution	Subpleural and basal predominant Often heterogeneous (areas of normal lung interspersed with fibrosis) Occasionally diffuse May be asymmetric	Subpleural and basal predominant Often heterogeneous (areas of normal lung interspersed with reticulation and traction bronchiectasis/bronchiolectasis)	Diffuse distribution without subpleural predominance	Peribronchovascular predominant with subpleural sparing (consider NSIP) Perilymphatic distribution (consider sarcoidosis) Upper- or mid-lung (consider fibrotic HP, CTD-ILD, and sarcoidosis) Subpleural sparing (consider NSIP or smoking-related IP)
CT features	Honeycombing with or without traction bronchiectasis/bronchiolectasis Presence of irregular thickening of interlobular septa Usually superimposed with a reticular pattern, mild GGOs May have pulmonary ossification	Reticular pattern with traction bronchiectasis/bronchiolectasis May have mild GGOs Absence of subpleural sparing	CT features of lung fibrosis that do not suggest any specific etiology	Lung findings ◦ Cysts (consider LAM, PLCH, LIP, and DIP) ◦ Mosaic attenuation or three-density sign (consider HP) ◦ Predominant GGO (consider HP, smoking-related disease, drug toxicity, and acute exacerbation of fibrosis) ◦ Profuse centrilobular micronodules (consider HP or smoking-related disease) ◦ Nodules (consider sarcoidosis) ◦ Consolidation (consider organizing pneumonia, etc.) Mediastinal findings ◦ Pleural plaques (consider asbestosis) ◦ Dilated esophagus (consider CTD)

The previous term, 'early UIP pattern,' has been eliminated to avoid confusion with 'interstitial lung abnormalities' described in the text. The term 'indeterminate for UIP' has been retained for situations in which the HRCT features do not meet UIP or probable UIP criteria and do not explicitly suggest an alternative diagnosis[7]. Reprinted from Raghu et al.[7], with permission from Oxford University Press.
HRCT: high-resolution computed tomography; UIP: usual interstitial pneumonia; NSIP: nonspecific interstitial pneumonia; HP: hypersensitivity pneumonitis; CTD: connective tissue disease; ILD: interstitial lung disease; IP: interstitial pneumonia; CT: computed tomography; GGO: ground-glass opacity; LAM: lymphangioleiomyomatosis; PLCH: pulmonary Langerhans cell histiocytosis; LIP: lymphoid interstitial pneumonia; DIP: desquamative interstitial pneumonia.

a prevalence of 64.9%[34].

Diagnosis

1. Clinical features

IPF should be considered in adults who present with unexplained chronic exertional dyspnea, cough, inspiratory crackles, and clubbing. The disease usually develops after the age of 50, occurs more often in men[35-37], and is strongly associated with a history of smoking[36,38-40]. Most cases follow a chronic, progressive course, and spontaneous improvement is rare. Complications such as right heart failure and peripheral edema may develop at advanced stages.

2. High-resolution computed tomography findings

High-resolution computed tomography (HRCT) characteristically shows a usual interstitial pneumonia (UIP) pattern in IPF. Imaging patterns on HRCT fall into four categories: UIP, probable UIP, indeterminate for UIP, and alternative diagnosis (Table 1)[7].

A UIP pattern is defined by honeycombing that predominates in the basal and peripheral lung zones and is often accompanied by traction bronchiectasis or bronchiolectasis (Figure 1)[41,42]. A UIP pattern on HRCT corresponds closely to histopathologic UIP findings[43-45].

A probable UIP pattern shows reticular abnormalities with traction bronchiectasis or bronchiolectasis, again predominantly in the basal and subpleural regions, and no features that suggest an alternative diagnosis. Such imaging findings frequently correspond to a histopathologic UIP pattern (Figure 2)[46].

The indeterminate for UIP category applies when computed tomography (CT) shows fibrosis that lacks features distinctive enough to support a specific diagnosis. The alternative diagnosis pattern, by contrast, shows features such as cysts, mosaic attenuation, and ground-glass opacities that point away from UIP and toward another diagnosis (Figures 3, 4).

3. Histopathologic findings

On low-power examination, a UIP pattern characteristically combines normal areas, interstitial inflammation, fibrosis, and honeycombing within the same specimen (Table 2 and Figure 5). As with HRCT findings, histopathologic findings fall into four categories: UIP, probable UIP, indeterminate for UIP, and alternative diagnosis.

A histopathologic UIP pattern comprises fibrotic lesions distributed mainly in subpleural or septal lo-

Figure 1. High-resolution computed tomography (HRCT) images show subpleural-predominant, lower lung–predominant honeycombing appearance. Honeycombing is usually associated with traction bronchiolectasis and a varying degree of ground-glass attenuation. The axial images (A, B) and coronal images (C) demonstrate typical features of usual interstitial pneumonia (UIP) pattern seen in idiopathic pulmonary fibrosis (IPF).

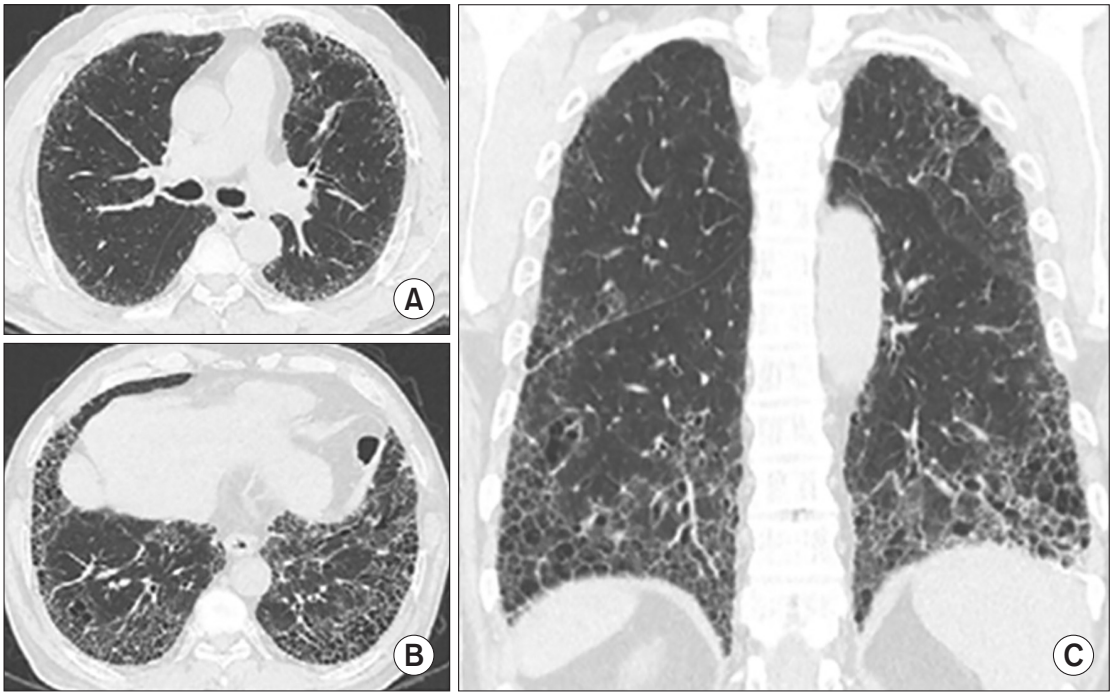

Figure 2. Probable usual interstitial pneumonia (UIP) pattern on high-resolution computed tomography (HRCT). Axial HRCT images (A, B) and coronal image (C) demonstrate features suggestive of a probable UIP pattern. Subpleural and basal predominant reticular abnormalities are evident, with traction bronchiectasis. Unlike definite UIP, honeycombing is absent in this case, which is a key differentiating feature.

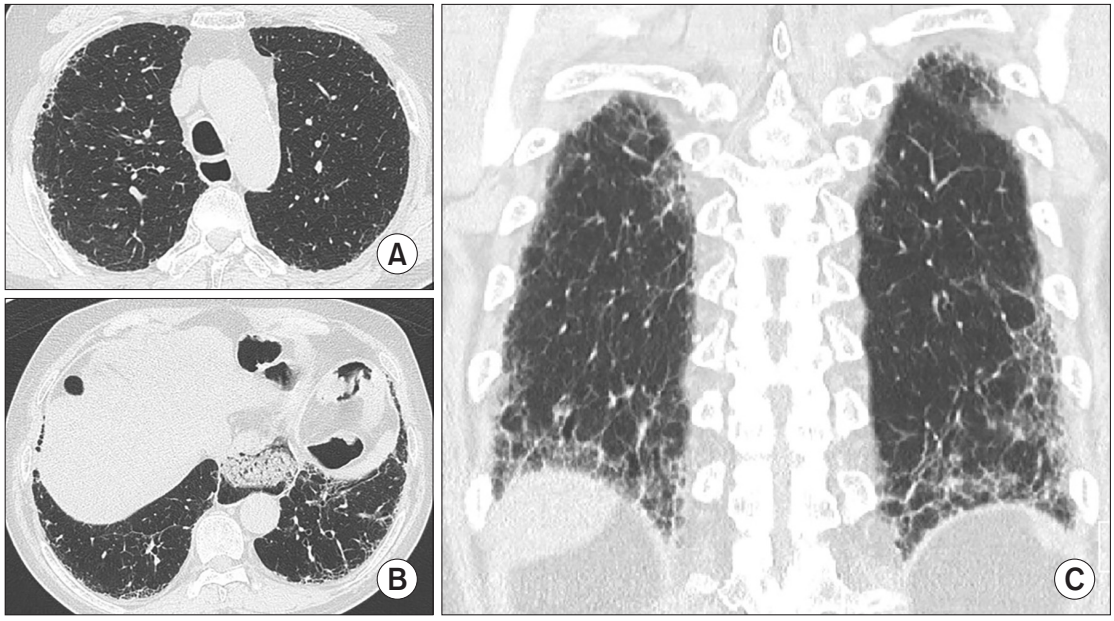

Figure 3. Alternative diagnosis other than usual interstitial pneumonia (UIP) pattern on high-resolution computed tomography (HRCT) (hypersensitivity pneumonitis). Axial HRCT images (A, B) and coronal image (C) demonstrate features consistent with hypersensitivity pneumonitis. Diffuse centrilobular nodules and ground-glass opacities are visible, along with mosaic attenuation, indicative of air trapping. The absence of subpleural honeycombing and the presence of these airway-centered abnormalities differentiate hypersensitivity pneumonitis from UIP.

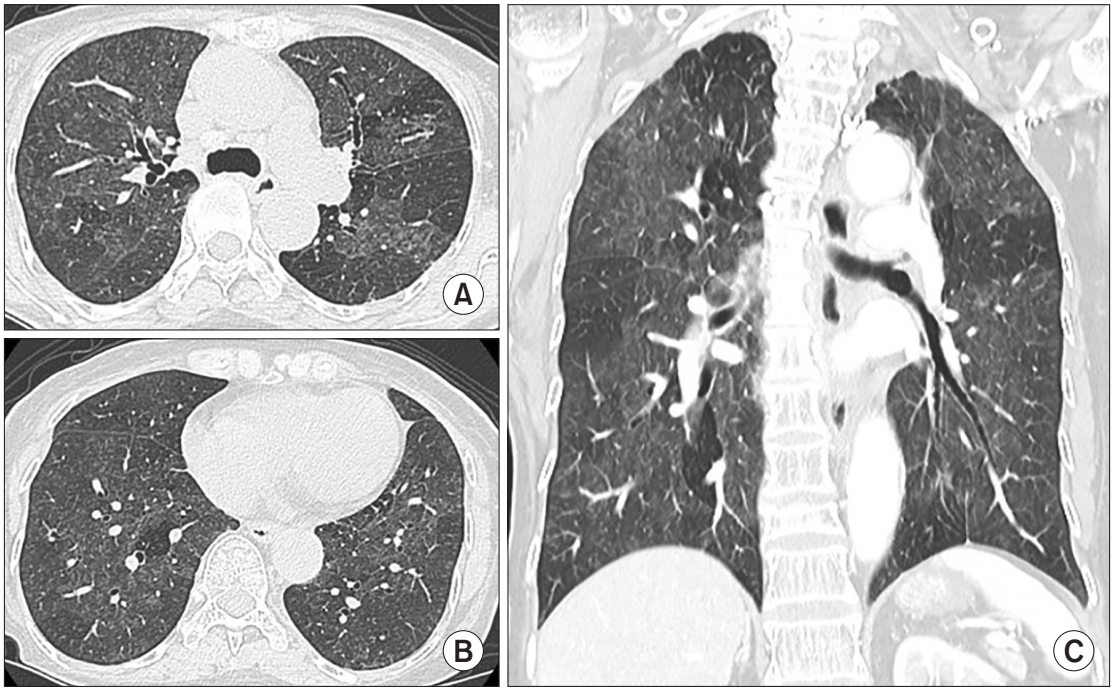

Figure 4. Alternative diagnosis other than usual interstitial pneumonia (UIP) pattern on high-resolution computed tomography (HRCT) (asbestosis). Axial HRCT images demonstrate findings consistent with asbestosis. Subpleural reticular opacities and pleural thickening are evident, predominantly in the lower lobes, which are characteristic features of asbestosis (A). The image on the right (B) highlights pleural plaques, a hallmark of prior asbestos exposure. These findings differentiate asbestosis from UIP by the presence of pleural abnormalities and the absence of honeycombing.

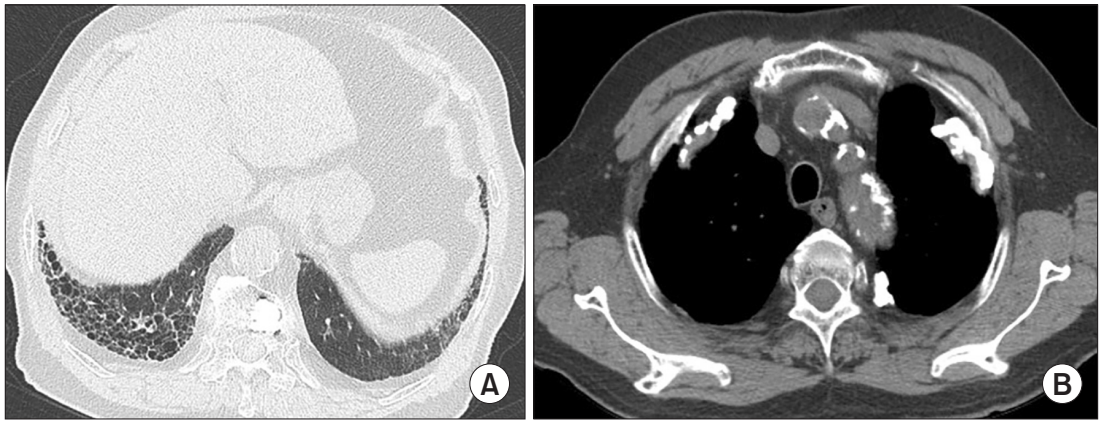

Table 2. Histopathology of UIP[6,7]

UIP pattern	Probable UIP	Indeterminate for UIP	Alternative diagnosis
Patchy dense fibrosis and architectural distortion Predominant subpleural and septal distribution Patchy distribution of fibrosis in the lung parenchyma Fibroblast foci Absence of features suggestive of an alternative diagnosis	Honeycombing only, or Several features of UIP, but a clear diagnosis of UIP/IPF is limited, and Absence of features suggesting an alternative diagnosis	Fibrosis with or without architectural distortion, with features suggesting a pattern other than UIP. Some histopathologic UIP features, but accompanied by features suggesting another diagnosis	Features of other histologic patterns of IIPs (e.g., absence of fibroblast foci or loose fibrosis) in all biopsies Histologic findings indicative of other diseases (e.g., hypersensitivity pneumonitis, Langerhans cell histiocytosis, sarcoidosis, LAM)

Reprinted from Raghu et al.[7], with permission from Oxford University Press.
UIP: usual interstitial pneumonia; IPF: idiopathic pulmonary fibrosis; IIP: idiopathic interstitial pneumonia; LAM: lymphangioleiomyomatosis.

cations, advanced fibrotic changes such as architectural distortion and honeycombing, and early fibrotic findings such as fibroblast foci, with no features that suggest an alternative diagnosis. Honeycomb areas consist of cystic fibrotic lesions that are filled with mucus and inflammatory cells and lined by bronchiolar epithelium, and smooth muscle hyperplasia of the interstitium commonly accompanies areas of fibrosis and honeycombing. Because other diseases can also produce a UIP pattern, differential diagnosis is essential, particularly against ILD associated with connective tissue disease, chronic hypersensitivity pneumonitis (extrinsic allergic alveolitis), and pneumoconiosis (particularly asbestosis).

4. Diagnostic approach

The diagnostic criteria and the algorithm (overview) for IPF are shown in Table 3 and Figure 6. Accurate diagnosis requires a multidisciplinary discussion among experienced pulmonologists, radiologists, and pathologists, in which other causes are excluded.

In patients with suspected ILD, clinicians should take a careful medical history and perform a physical examination to identify known triggers of ILD, such as medications, connective tissue diseases, or environmental exposures. Once chest HRCT has been obtained, a multidisciplinary team decides whether additional tests, such as bronchoalveolar lavage (BAL) or surgical lung biopsy, are needed.

Figure 5. Histopathological features of usual interstitial pneumonia (UIP). (A) Spatial heterogeneity: subpleural and septal fibrosis, demonstrating a patchy and uneven distribution of fibrosis (×20). (B) Honeycombing with structural changes: presence of a honeycomb pattern, indicative of advanced fibrotic changes with cystic spaces in the lung (×40). (C) Progressive fibrosis and fibroblast foci: co-occurrence of advanced fibrosis with fibroblast foci, reflecting early fibrotic changes and disease progression (×100).

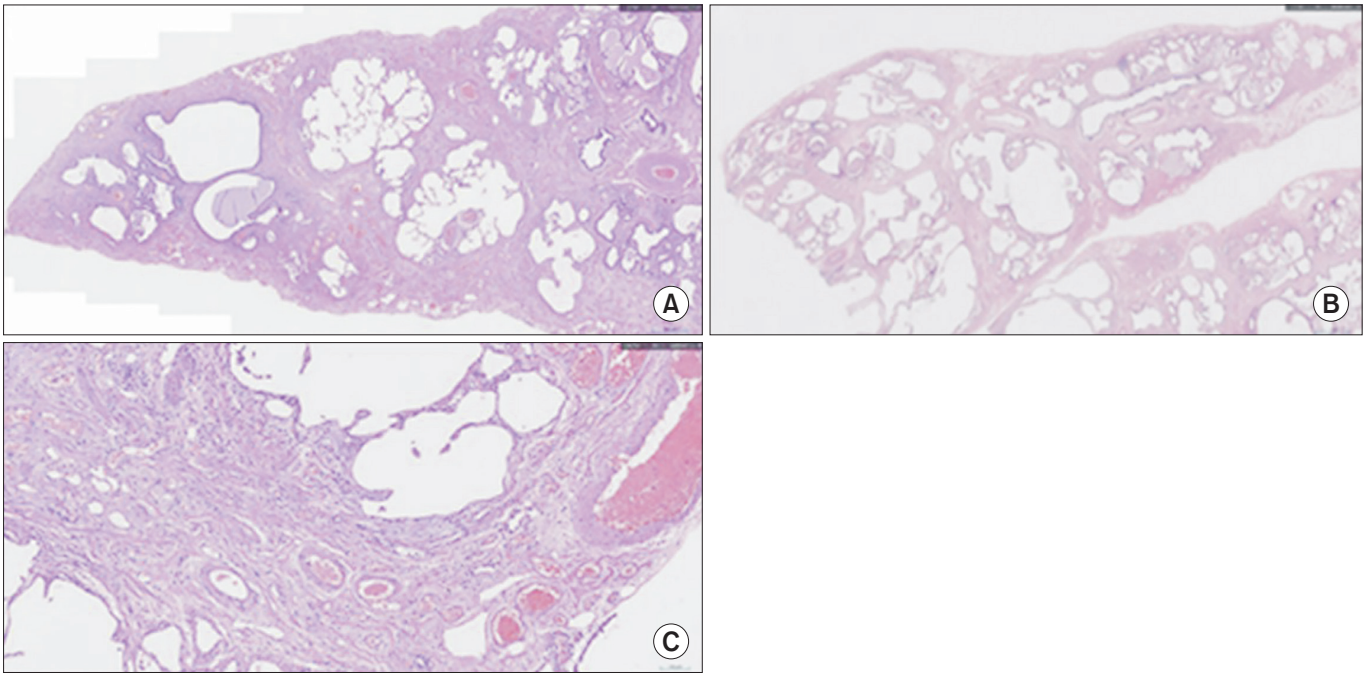

Table 3. Diagnosis of IPF based on the combination of HRCT findings and histopathologic patterns

IPF suspected*		Histopathology pattern			
		UIP	Probable UIP	Indeterminate for UIP or biopsy not performed	Alternative diagnosis
HRCT pattern	UIP	IPF	IPF	IPF	Non-IPF dx
	Probable UIP	IPF	IPF	IPF (Likely)†	Non-IPF dx
	Indeterminate	IPF	IPF (Likely)†	Indeterminate‡	Non-IPF dx
	Alternative diagnosis	IPF (Likely)†	Indeterminate‡	Non-IPF dx	Non-IPF dx

Reprinted from Raghu et al.[7], with permission from Oxford University Press.
*'Clinically suspected of having IPF' is defined as unexplained patterns of bilateral pulmonary fibrosis on chest radiography or chest computed tomography, bibasilar inspiratory crackles, and age >60 years. Middle-aged adults (40 to <60 years old) can rarely present with otherwise similar clinical features, especially in patients with features suggesting familial pulmonary fibrosis. †IPF (Likely) is the most likely diagnosis when any of the following features are present: (1) moderate to severe traction bronchiectasis and/or bronchiolectasis (defined as mild traction bronchiectasis and/or bronchiolectasis in four or more lobes, including the lingula as a lobe, or moderate to severe traction bronchiectasis in two or more lobes) in a man >50 years old or in a woman >60 years old, (2) extensive (>30%) reticulation on HRCT and age >70 years, (3) increased neutrophils and/or absence of lymphocytosis in BAL fluid, and (4) multidisciplinary discussion produces a confident diagnosis of IPF. ‡Indeterminate for IPF: (1) without an adequate biopsy, the diagnosis remains indeterminate, and (2) with an adequate biopsy may be reclassified to a more specific diagnosis after multidisciplinary discussion and/or additional consultation. Adapted from the 2022 guideline.
IPF: idiopathic pulmonary fibrosis; HRCT: high-resolution computed tomography; UIP: usual interstitial pneumonia; dx: diagnosis.

When no cause can be identified, IPF can be diagnosed without biopsy if HRCT shows characteristic findings, namely a UIP or probable UIP pattern. Otherwise, biopsy is required, and the diagnosis rests on the combination of HRCT and histopathologic findings (Figure 6).

Figure 6. Diagnostic algorithm for idiopathic pulmonary fibrosis (IPF), developed using consensus by discussion. Reprinted from Raghu et al.[7], with permission from Oxford University Press. *Patients with a radiological pattern of probable usual interstitial pneumonia (UIP) can receive a diagnosis of IPF after multidisciplinary discussion (MDD) without confirmation by lung biopsy in the appropriate clinical setting (e.g., 60 years old, male, smoker). Bronchoalveolar lavage (BAL) may be appropriate in some patients with a probable UIP pattern. †BAL may be performed before MDD in some patients evaluated in experienced centers. ‡Transbronchial lung cryobiopsy (TBLC) may be preferred to surgical lung biopsy (SLB) in centers with appropriate expertise and/or in some patient populations, as described in the text. A subsequent SLB may be justified in some patients with nondiagnostic findings on TBLC[7]. HRCT: high-resolution computed tomography.

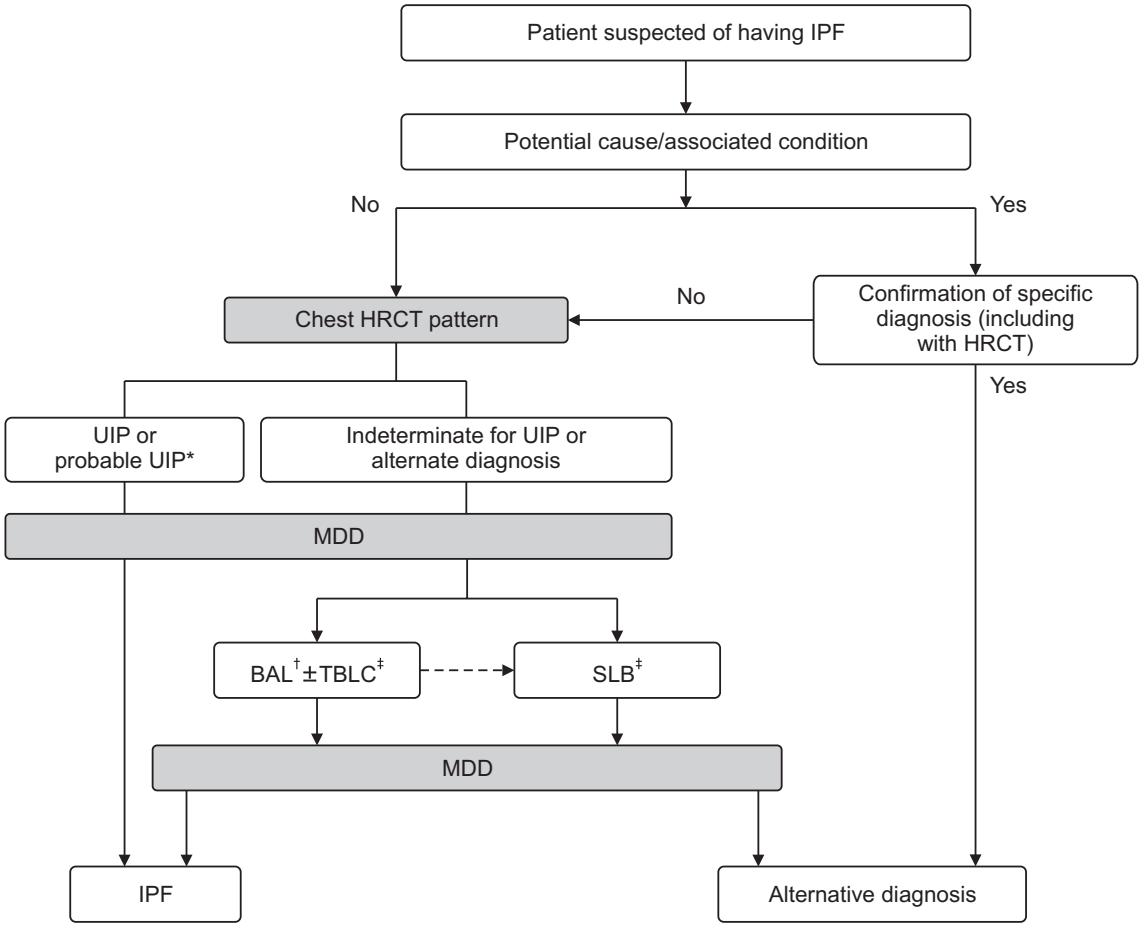

1) History taking and basic evaluation

IPF should be suspected in older patients (particularly those aged ≥60 years) who present with chronic dyspnea or dry cough together with physical findings such as clubbing or inspiratory crackles on auscultation. Increased opacities in the lower lung zones on chest radiography further support this suspicion[6]. Detailed history taking is also essential in younger patients aged 40 to 60 years, in whom a family history of pulmonary fibrosis raises the possibility of IPF.

A thorough occupational history should be taken to rule out smoking-related and occupational lung diseases, and the environmental exposure history should be reviewed to assess the possibility of hypersensitivity pneumonitis. Medication use and any history of radiation therapy should also be investigated. Because connective tissue diseases may be involved, symptoms affecting the joints and skin warrant careful evaluation. ILD can precede extrapulmonary manifestations such as arthritis or skin changes, so even asymptomatic patients should undergo autoantibody testing that includes antinuclear antibody and rheumatoid factor. When other diseases are suspected, additional autoantibody tests, including anti-cyclic citrullinated peptide (anti-CCP), anti-Sjögren's syndrome-related antigen A/B (anti-SSA/SSB), anti-topoisomerase I (anti-Scl-70), and antineutrophil cytoplasmic antibodies (ANCA), should be performed as appropriate[6].

2) HRCT

Chest HRCT is essential to the diagnostic process for IPF and is a sensitive technique for detecting changes in the lung parenchyma. It is performed without contrast, using thin-section volumetric HRCT images (≤1.5 mm slice thickness)[47]. Additional imaging in the expiratory phase and in the prone position is recommended to assess associated conditions such as air trapping or atelectasis; these techniques help distinguish ILDs involving the small airways or pseudolesions[6]. When IPF of unknown cause is suspected after thorough history taking and autoantibody testing, HRCT should be the first diagnostic step, and a multidisciplinary approach then determines whether additional tests, such as surgical lung biopsy, are needed.

3) Bronchoalveolar lavage

In patients with IPF, BAL often shows a higher proportion of neutrophils than in healthy individuals or in patients with other lung diseases, although similar findings occur in connective tissue disease-related lung disease and other conditions. When chest CT does not show a UIP pattern, analyzing the cellular fraction and the CD4/CD8 ratio in BAL fluid can help differentiate IPF from other ILDs[7].

4) Surgical lung biopsy

The need for surgical lung biopsy should be determined after HRCT and multidisciplinary discussion. Because histopathologic patterns may differ between lobes in the same patient, tissue samples should be taken from at least two separate lobes[6]. Any decision to proceed must weigh the diagnostic benefit against the procedural risk, taking patient age, physiologic impairment, and comorbidities into account.

5) Transbronchial lung cryobiopsy

Transbronchial lung cryobiopsy (TBLC) performed by bronchoscopy has recently been introduced as a tissue-sampling method for diagnosing ILD[48,49]. One study that compared TBLC with conventional surgical lung biopsy found no significant difference in diagnostic yield or complications between the two methods[48]. Because institutional expertise varies and the procedure has not been standardized, TBLC should be considered an alternative to surgical lung biopsy only in centers with substantial experience in the technique[7].

Treatment

Pirfenidone is an oral antifibrotic agent that attenuates the decline in forced vital capacity (FVC) in clinical studies[26,50-52]. This protective effect on lung function has been observed both in patients with an FVC <80% and in those with an FVC ≥80%[53], and it persists regardless of the degree of FVC impairment[54]. In the CAPACITY[50] trials and the RECAP[54] extension study, FVC declined more slowly in the pirfenidone groups than in the control group, and the rate of decline slowed further in control patients after they crossed over to pirfenidone[54]. The benefit extended across subgroups defined by age (≤65, >65, and >75 years), sex, race, diffusing capacity, and 6-minute walk test results[55].

In the Czech IPF cohort, the 5-year survival rate among patients with IPF who received pirfenidone was 55.9%, significantly higher than the 31.5% observed in those who did not receive treatment[56]. Overall mortality and IPF-related mortality were also significantly lower in the pirfenidone group than in controls[50].

Nintedanib similarly protects lung function in patients with an FVC ≥90% and in those with an FVC <90%[57]. A meta-analysis of the TOMORROW trial[58] (2011) and the INPULSIS-1 and INPULSIS-2 trials[25] (2014) found that nintedanib significantly reduced on-treatment mortality[59].

A pooled analysis of the CAPACITY 1, CAPACITY 2, ASCEND, INPULSIS-1, and INPULSIS-2 clinical trials showed that antifibrotic agents significantly slowed lung function decline relative to control treatment[60].

The 2018 KATRD clinical practice guideline for ILD recommended antifibrotic agents such as pirfenidone and nintedanib for preventing FVC decline, with a high level of evidence[3]. The 2023 revision framed the efficacy of these agents as key clinical questions (KQs) addressing lung function and mortality; summaries of the evidence for each KQ appear in the Supplementary Materials and Methods.

KQ 1-1. In patients with IPF, does pirfenidone protect against FVC decline compared with the control group?

A. We recommend the use of pirfenidone to protect against FVC decline in patients with clinically or histologically diagnosed IPF. (Evidence level: Moderate, Recommendation grade: Strong recommendation)

KQ 1-2. In patients with IPF, does pirfenidone reduce mortality compared with the control group?

A. We recommend the use of pirfenidone to reduce mortality in patients with clinically or histologically diagnosed IPF. (Evidence level: Moderate, Recommendation grade: Strong recommendation)

KQ 2-1. In patients with IPF, does nintedanib protect against FVC decline compared with the control group?

A. We recommend the use of nintedanib in patients

with clinically or histologically diagnosed IPF to protect against FVC decline. (Evidence level: Moderate, Recommendation grade: Strong recommendation)

KQ 2-2. In patients with IPF, does nintedanib reduce mortality compared with the control group?

A. We recommend the use of nintedanib in patients with clinically or histologically diagnosed IPF to reduce mortality. (Evidence level: Moderate, Recommendation grade: Strong recommendation)

Nonpharmacologic Therapy

IPF is a chronic, progressive fibrotic lung disease that currently has no curative treatment other than lung transplantation, so healthcare providers must manage it along several dimensions to preserve lung function and quality of life. Such care combines antifibrotic drug therapy to inhibit disease progression, pulmonary rehabilitation, oxygen therapy, symptomatic treatment of cough and dyspnea, management of comorbidities and complications, and education and counseling about treatment goals and disease progression (Figure 7)[4,7,61].

Comorbidities

Patients with IPF may have a wide range of respiratory and nonrespiratory comorbidities, including pulmonary, gastrointestinal, cardiovascular and cerebrovascular, metabolic, and psychiatric conditions, which clinicians often overlook. In a recent prospective cohort study of 3,580 patients with IPF, 91.3% had at least one comorbidity and 37.8% had four or more[62]. Shared risk factors such as smoking, advanced age, and male sex probably explain this clustering. Comorbidities aggravate symptoms and shorten survival, and they account for approximately 30% of deaths in this population[63]; PH, lung cancer, and cardiovascular disease in particular are associated with shorter survival[63]. The 2023 revised edition highlights the comorbidities of greatest clinical importance in IPF (Table 4).

1. Respiratory diseases

1) Lung cancer

IPF is an independent risk factor for lung cancer even after adjustment for key factors such as smoking. Lung cancer occurs more than eight times as often in patients with IPF as in the general population[64], and its estimated prevalence in this group ranges from 3% to 48%[65]. Data from the Korean National Health Insurance Service showed a lung cancer prevalence of 6.4% and a 5-year cumulative incidence of 7% in patients with

Figure 7. Multidisciplinary care in idiopathic pulmonary fibrosis (IPF). As IPF is a chronic and refractory disease, often associated with many comorbidities including pharmacologic and nonpharmacologic treatments, control of comorbidities, as well as education and counseling, is needed for the best care of the patients. GERD: gastroesophageal reflux disease; PH: pulmonary hypertension.

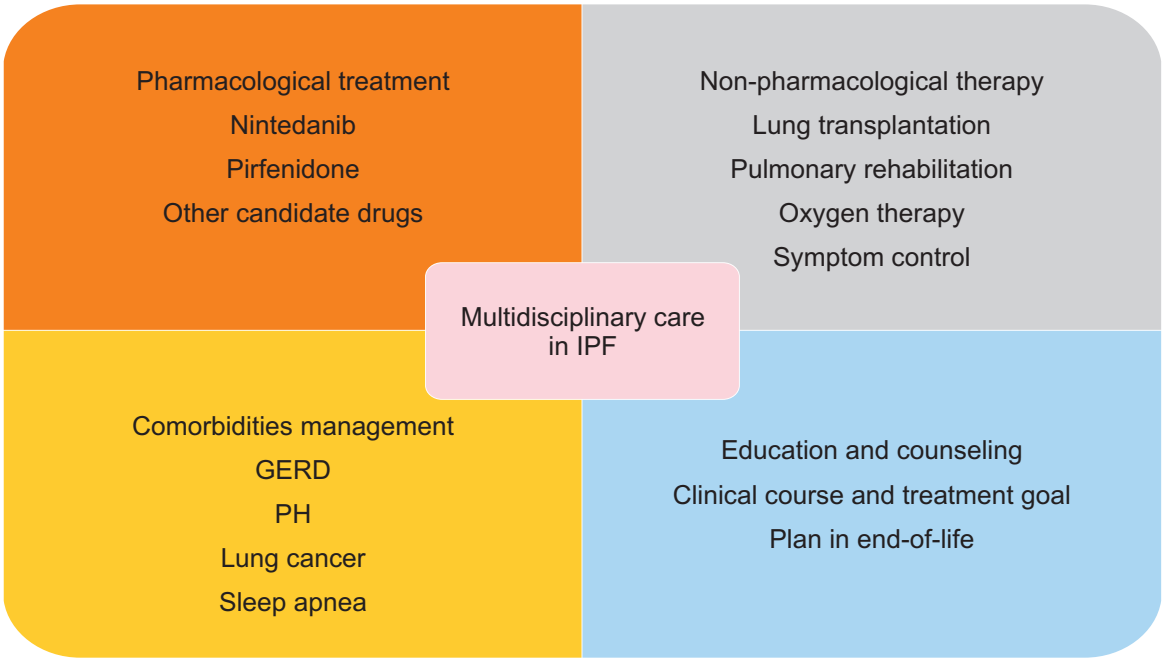

Table 4. Comorbidities commonly occurring in patients with IPF

Comorbidities	Diseases
Respiratory diseases	COPD, emphysema
	Lung cancer
	PH
	Sleep apnea
	PTE, VTE
Cerebro-cardiovascular diseases	IHD
	Arrhythmia
	CHF
	CVA
Gastrointestinal and metabolic diseases	GERD
	DM
	Hyperlipidemia
	Hyperthyroidism
Psychological diseases	Depression
	Anxiety

IPF: idiopathic pulmonary fibrosis; COPD: chronic obstructive pulmonary disease; PH: pulmonary hypertension; PTE: pulmonary thromboembolism; VTE: venous thromboembolism; IHD: ischemic heart disease; CHF: chronic heart failure; CVA: cerebrovascular accident; GERD: gastroesophageal reflux disease; DM: diabetes mellitus.

IPF[66]. Mortality is more than five times higher in patients with IPF and lung cancer than in those without lung cancer[67], partly because surgery, chemotherapy, and radiotherapy can all exacerbate IPF. Interestingly, pirfenidone and nintedanib have shown antitumor effects, which warrants further investigation[68-70].

2) Pulmonary hypertension

PH occurs in approximately 14% of patients with IPF and mild restrictive lung disease and in 30%–50% of those with severe IPF[31]. PH is associated with more than a threefold increase in mortality and reduces quality of life and exercise capacity[63]. Patients with IPF should be evaluated for PH when they have dyspnea or hypoxemia disproportionate to their lung function, signs of right heart failure, a marked reduction in diffusing capacity, or radiologic findings such as pulmonary artery enlargement or right ventricular hypertrophy.

3) Emphysema or COPD

The prevalence of emphysema in IPF ranges from 8% to 51%[65]. CPFE, characterized by upper-lobe emphysema and lower-lobe fibrosis, is present in approximately 8%[32] to 30%[71] of patients with IPF. It carries a higher incidence of lung cancer and PH than IPF alone[65], although mortality is comparable to that of IPF without emphysema[72]. No specific treatment exists for CPFE, but general measures such as oxygen therapy, pulmonary rehabilitation, and inhaled bronchodilators for coexisting COPD can be applied, and nintedanib has shown some efficacy in patients with CPFE enrolled in IPF clinical trials[73].

4) Sleep apnea

Sleep apnea is notably common in patients with IPF, with prevalences of 59% to 88% in international studies[74,75] and 64.9% at a single Korean institution[34]. Reduced lung volume increases upper airway instability and resistance and thereby promotes sleep apnea, and the resulting intermittent hypoxemia may in turn aggravate pulmonary fibrosis[76]. In one study, patients with IPF and moderate-to-severe sleep apnea who adhered to continuous positive airway pressure therapy for 1 year had significantly better quality of life, sleep quality, and survival than nonadherent patients[77].

2. Nonrespiratory diseases

1) GERD

GERD is common in patients with IPF and often occurs without typical reflux symptoms; one study found asymptomatic GERD in approximately 50% of patients with IPF[40]. GERD may contribute to the development and progression of IPF and frequently causes chronic cough. Recent large-scale studies and meta-analyses, however, have shown that neither medical nor surgical treatment of GERD significantly affects IPF progression or mortality[78-81]. On this basis, the 2022 updated guidelines conditionally recommend against treating GERD solely to improve respiratory symptoms in patients with IPF[7].

2) Cardiovascular and cerebrovascular diseases

Cardiovascular disease is present in approximately 78% of patients with IPF[27], and ischemic heart disease shows the strongest association with mortality. A Finnish study found that acute exacerbation was the leading cause of death in patients with IPF (67.5%), followed by ischemic heart disease (14.8%)[82], and the incidence of ischemic heart disease in IPF exceeds that in both the general population and patients with COPD[83]. Chronic hypoxemia and the severe tissue injury and fibrosis associated with IPF may induce a prothrombotic state and thereby account for this excess risk[65].

3) Anxiety and depression

The chronic, refractory nature of IPF, together with dyspnea and activity limitations, produces a high prevalence of anxiety (30%–50%) and depression (20%–30%) among patients with IPF[31]. Psychological distress in turn worsens dyspnea. A Korean study of 112 patients with IPF reported anxiety in 21.4% and depression in 25.9%[84]. Despite this high prevalence, only about 25% of affected patients receive treatment[85].

Acute Exacerbation

This section covers only the updated epidemiology and treatment of acute exacerbations. Among Asian patients, the 3-year incidence of acute exacerbation exceeds 20%[86]; among Korean patients, the 1-year incidence is 6.72% and the 3-year incidence is 16.6%[87]. International guidelines recommend high-dose corticosteroid therapy as a supportive measure for acute exacerbations[7]. No standard dose has been established, but a commonly used regimen is methylprednisolone 500 to 1,000 mg daily for 3 days, followed by gradual tapering[88].

Some studies have suggested that early use of immunosuppressive agents such as cyclophosphamide and tacrolimus[89,90], as well as polymyxin B-immobilized fiber column hemoperfusion[91], may also be beneficial; however, further study is needed.

Treating GERD has not been shown to prevent acute exacerbations and is therefore not recommended[7]. Supportive measures such as oxygen therapy for dyspnea or hypoxemia are commonly provided. Intubation and mechanical ventilation are generally avoided because of the poor prognosis, except when respiratory failure has a treatable cause or lung transplantation is being considered.

In one meta-analysis, antifibrotic therapy reduced the rate of acute exacerbations in patients with IPF by 37% and delayed their onset compared with no antifibrotic treatment[92]. The present revision therefore framed the efficacy of antifibrotic agents in preventing acute exacerbations as a KQ and addressed it through a systematic literature review and meta-analysis.

KQ 3. In patients with clinically or histologically diagnosed IPF, does antifibrotic therapy (pirfenidone or nintedanib) reduce the incidence of acute exacerbations compared with no antifibrotic therapy?

A. We conditionally recommend the use of antifibrotic agents (pirfenidone or nintedanib) in patients with

Table 5. Absolute contraindications to lung transplantation[95]

1. Lack of patient willingness to accept transplantation
2. Malignancy with high risk of recurrence or death related to cancer
3. Glomerular filtration rate <40 mL/min/1.73 m^2 unless being considered for multi-organ transplant
4. Acute coronary syndrome or myocardial infarction within 30 days (excluding demand ischemia)
5. Stroke within 30 days
6. Liver cirrhosis with portal hypertension or synthetic dysfunction unless being considered for multi-organ transplant
7. Acute liver failure
8. Acute renal failure with rising creatinine or on dialysis with a low likelihood of recovery
9. Septic shock
10. Active extrapulmonary or disseminated infection
11. Active tuberculosis infection
12. HIV infection with detectable viral load
13. Limited functional status (e.g., non-ambulatory) with poor rehabilitation potential after transplantation
14. Progressive cognitive impairment
15. Repeated episodes of non-adherence without evidence of improvement (footnote: For pediatric patients this is not an absolute contraindication and ongoing assessment of non-adherence should occur as they progress through different developmental stages.)
16. Active substance use or dependence including current tobacco use, vaping, marijuana smoking, or IV drug use
17. Other severe uncontrolled medical condition expected to limit survival after transplantation

HIV: human immunodeficiency virus; IV: intravenous.

clinically or histologically diagnosed IPF to prevent acute exacerbations. (Evidence level: Moderate, Recommendation grade: Conditional recommendation)

Lung Transplantation

On the basis of a systematic literature review and meta-analysis conducted during the development of the 2018 Korean guidelines, we suggested that patients with IPF undergo lung transplantation at an appropriate time to improve survival (strong recommendation, moderate confidence in estimates of effect)[5]. The most common indications for lung transplantation are ILD, COPD, cystic fibrosis, alpha-1 antitrypsin deficiency, and primary PH[93], which together account for approximately 85% of lung transplant recipients worldwide; the remaining 15% have various other end-stage pulmonary diseases. In South Korea, IPF accounts for 50% of lung transplantations, followed by post-transplant bronchiolitis obliterans (6%) and bronchiectasis (5%). Unlike in other countries, COPD accounts for only 1% of indications for lung transplantation in Korea[94].

1. Patients requiring lung transplantation

The indications for lung transplantation are as follows[95]: (1) advanced lung disease for which medical treatment is ineffective or unavailable; (2) a greater than 50% risk of death from the lung disease within the next 2 years without transplantation; and (3) an estimated post-transplant survival rate of at least 80% at 5 years.

Table 5 summarizes the absolute contraindications to lung transplantation[95]. The timing of referral to a transplant center varies with each patient's circumstances and with the criteria of the individual center. Table 6 shows the referral criteria for transplantation evaluation established by the International Society for Heart and Lung Transplantation (ISHLT)[95].

2. Evaluation of potential lung transplant candidates

Evaluating a potential lung transplant candidate is a comprehensive process. It covers the patient's medical history, physical examination, laboratory tests (e.g., complete blood count and screening for multiple viral infections), and imaging and functional studies (e.g., chest CT, ventilation/perfusion scans, cardiac evaluations, left and right heart catheterization, osteoporosis and cancer screening, and assessments of gastroesophageal reflux and gastrointestinal motility), as well as vaccination status and psychosocial assessment.

A multidisciplinary team at a lung transplant center typically conducts this evaluation, including pulmonologists who specialize in lung transplantation, transplant surgeons, nurses, social workers, and other specialists. The specific tests and evaluations may vary with the patient's age, medical history, and the protocols of the transplant center.

3. Survival rates of lung transplantation

Lung transplantation confers substantial survival benefits: the ISHLT reports global survival rates of 79% at 1 year, 63% at 5 years, and 44% at 10 years. Outcomes differ by underlying condition; IPF is associated with a 5-year survival rate of approximately 50%, whereas patients with cystic fibrosis reach a higher rate of around 70%.

Lung transplantation began in South Korea in 1996[96], and recent single-center studies have shown promising results, with 1- and 5-year survival rates of approximately 75.5% and 61.8%, respectively, reflecting outcomes that are comparable to or better than global

Table 6. Referral criteria for lung transplantation in patients with ILD[95]

Referral should be made at the time of diagnosis, even if a patient is being initiated on therapy, for histopathologic UIP or radiographic evidence of a probable or definite UIP pattern.
Any form of pulmonary fibrosis with FVC of <80% predicted or DLCO <40% predicted.
Any form of pulmonary fibrosis with one of the following in the past 2 years: • Relative decline in FVC ≥10% • Relative decline in DLCO ≥15% • Relative decline in FVC ≥5% in combination with worsening of respiratory symptoms or radiographic progression
Supplemental oxygen requirement either at rest or on exertion.
For inflammatory ILDs, progression of disease (either on imaging or pulmonary function) despite treatment.
For patients with connective tissue disease or familial pulmonary fibrosis, early referral is recommended as extrapulmonary manifestations may require special consideration.

ILD: interstitial lung disease; UIP: usual interstitial pneumonia; FVC: forced vital capacity; DLCO: diffusing capacity of the lung for carbon monoxide.

standards[97].

Conclusion

This updated Korean guideline for IPF incorporates recent evidence to improve diagnostic accuracy and standardize management. It supports the appropriate use of antifibrotic therapy, which slows FVC decline, reduces mortality, and may lower the risk of acute exacerbations.

Authors' Contributions

Conceptualization: Choi HS, Yoon HY, Park SY, Lee J, Kang JY, Cho JY, Choi WI. Methodology: Choi HS, Yoon HY, Park SY, Lee J, Kang JY, Cho JY, Jung SS, Choi WI. Formal analysis: Choi HS, Yoon HY, Park SY, Lee J, Kang JY, Cho JY, Choi WI. Data curation: Choi HS, Yoon HY, Park SY, Lee J, Kang JY, Cho JY, Choi WI. Software: Choi HS, Yoon HY, Park SY, Lee J, Kang JY, Cho JY, Choi WI. Validation: Choi HS, Yoon HY, Park SY, Lee J, Kang JY, Cho JY, Choi WI. Investigation: Choi HS, Yoon HY, Park SY, Lee J, Kang JY, Cho JY, Choi WI. Writing - original draft preparation: Choi HS. Writing - review and editing: Choi HS, Yoon HY, Park SY, Lee J, Kang JY, Cho JY, Choi WI. Approval of the final manuscript: all authors.

Conflicts of Interest

Hee-Young Yoon is an early career editorial board member of the journal, but she was not involved in the peer reviewer selection, evaluation, or decision process of this article. No other potential conflicts of interest relevant to this article were reported.

Funding

This study was supported by the National Research Foundation of Korea (NRF) grant funded by the Korean government (MSIT) (RS-2023-00274884).

Supplementary Material

Supplementary material can be found in the journal homepage (http://www.e-trd.org).

Supplementary Table S1. Level of evidence and definition.

Supplementary Table S2. Grade of recommendation.

Supplementary Table S3. GRADE summary of meta-analyses for pirfenidone key questions.

Supplementary Table S4. GRADE summary of meta-analyses for nintedanib key questions.

Supplementary Table S5. GRADE summary of meta-analyses for the effect of antifibrotics on prevention of acute exacerbation.

Supplementary Figure S1. Difference between nintedanib and control for all-cause mortality.

Supplementary Figure S2. Flow chart of the literature search for pirfenidone Population, Intervention, Comparison, Outcome (PICO).

Supplementary Figure S3. Risk difference of percentage of study population between pirfenidone and control with forced vital capacity decreased by more than 10%.

Supplementary Figure S4. Comparison of all-cause mortality between the pirfenidone and placebo control group.

Supplementary Figure S5. Comparison of idiopathic pulmonary fibrosis-related mortality between the pirfenidone group and the placebo control group.

Supplementary Figure S6. Flow chart for literature search on nintedanib in idiopathic pulmonary fibrosis patients for Population, Intervention, Comparison, Outcome (PICO).

Supplementary Figure S7. Effect of nintedanib on forced vital capacity protection in patients with idiopathic pulmonary fibrosis.

Supplementary Figure S8. Flow chart for literature search for antifibrotics for prevention of acute exacerbations Population, Intervention, Comparison, Outcome (PICO).

Supplementary Figure S9. Meta-analysis for effect of antifibrotics for prevention of acute exacerbations.

References

1. American Thoracic Society; European Respiratory Society. American Thoracic Society/European Respiratory Society international multidisciplinary consensus classification of the idiopathic interstitial pneumonias. Am J Respir Crit Care Med 2002;165:277-304.
2. American Thoracic Society. Idiopathic pulmonary fibrosis: diagnosis and treatment. International consensus statement. Am J Respir Crit Care Med 2000;161(2 Pt 1):646-64.
3. The Korean Academy of Tuberculosis and Respiratory Diseases. Interstitial lung disease clinical practice guideline. Seoul: Medrang; 2018.
4. Raghu G, Collard HR, Egan JJ, Martinez FJ, Behr J, Brown KK, et al. An official ATS/ERS/JRS/ALAT statement: idiopathic pulmonary fibrosis: evidence-based guidelines for diagnosis and management. Am J Respir Crit Care Med 2011;183:788-824.
5. Lee SH, Yeo Y, Kim TH, Lee HL, Lee JH, Park YB, et al.

Korean guidelines for diagnosis and management of interstitial lung diseases: Part 2. Idiopathic pulmonary fibrosis. Tuberc Respir Dis (Seoul) 2019;82:102-17.
6. Raghu G, Remy-Jardin M, Myers JL, Richeldi L, Ryerson CJ, Lederer DJ, et al. Diagnosis of idiopathic pulmonary fibrosis: an official ATS/ERS/JRS/ALAT clinical practice guideline. Am J Respir Crit Care Med 2018;198:e44-68.
7. Raghu G, Remy-Jardin M, Richeldi L, Thomson CC, Inoue Y, Johkoh T, et al. Idiopathic pulmonary fibrosis (an update) and progressive pulmonary fibrosis in adults: an official ATS/ERS/JRS/ALAT clinical practice guideline. Am J Respir Crit Care Med 2022;205:e18-47.
8. Guyatt G, Oxman AD, Akl EA, Kunz R, Vist G, Brozek J, et al. GRADE guidelines: 1. Introduction-GRADE evidence profiles and summary of findings tables. J Clin Epidemiol 2011;64:383-94.
9. Guyatt GH, Oxman AD, Vist GE, Kunz R, Falck-Ytter Y, Alonso-Coello P, et al. GRADE: an emerging consensus on rating quality of evidence and strength of recommendations. BMJ 2008;336:924-6.
10. Andrews JC, Schunemann HJ, Oxman AD, Pottie K, Meerpohl JJ, Coello PA, et al. GRADE guidelines: 15. Going from evidence to recommendation-determinants of a recommendation's direction and strength. J Clin Epidemiol 2013;66:726-35.
11. Scientific Committee of the Korean Academy of Tuberculosis and Respiratory Diseases. 2008 National survey of idiopathic interstitial pneumonia in Korea. Tuberc Respir Dis 2009;66:141-51.
12. Duchemann B, Annesi-Maesano I, Jacobe de Naurois C, Sanyal S, Brillet PY, Brauner M, et al. Prevalence and incidence of interstitial lung diseases in a multi-ethnic county of Greater Paris. Eur Respir J 2017;50:1602419.
13. Han SH, Mok Y, Jee SH, Danoff SK. Incidence and mortality of idiopathic pulmonary fibrosis in South Korea. Am J Respir Crit Care Med 2013;187(Suppl 1):A1460.
14. Lai CC, Wang CY, Lu HM, Chen L, Teng NC, Yan YH, et al. Idiopathic pulmonary fibrosis in Taiwan: a population-based study. Respir Med 2012;106:1566-74.
15. Natsuizaka M, Chiba H, Kuronuma K, Otsuka M, Kudo K, Mori M, et al. Epidemiologic survey of Japanese patients with idiopathic pulmonary fibrosis and investigation of ethnic differences. Am J Respir Crit Care Med 2014;190:773-9.
16. Kim SW, Myong JP, Yoon HK, Koo JW, Kwon SS, Kim YH. Health care burden and medical resource utilisation of idiopathic pulmonary fibrosis in Korea. Int J Tuberc Lung Dis 2017;21:230-5.
17. Lee HE, Myong JP, Kim HR, Rhee CK, Yoon HK, Koo JW. Incidence and prevalence of idiopathic interstitial pneumonia and idiopathic pulmonary fibrosis in Korea. Int J Tuberc Lung Dis 2016;20:978-84.
18. Fernandez Perez ER, Daniels CE, Schroeder DR, St Sauver J, Hartman TE, Bartholmai BJ, et al. Incidence, prevalence, and clinical course of idiopathic pulmonary fibrosis: a population-based study. Chest 2010;137:129-37.
19. Tarride JE, Hopkins RB, Burke N, Guertin JR, O'Reilly D, Fell CD, et al. Clinical and economic burden of idiopathic pulmonary fibrosis in Quebec, Canada. Clinicoecon Outcomes Res 2018;10:127-37.
20. Raghu G, Chen SY, Yeh WS, Maroni B, Li Q, Lee YC, et al. Idiopathic pulmonary fibrosis in US Medicare beneficiaries aged 65 years and older: incidence, prevalence, and survival, 2001-11. Lancet Respir Med 2014;2:566-72.
21. Harari S, Madotto F, Caminati A, Conti S, Cesana G. Epidemiology of idiopathic pulmonary fibrosis in Northern Italy. PLoS One 2016;11:e0147072.
22. Raghu G, Chen SY, Hou Q, Yeh WS, Collard HR. Incidence and prevalence of idiopathic pulmonary fibrosis in US adults 18-64 years old. Eur Respir J 2016;48:179-86.
23. Moon SW, Kim SY, Chung MP, Yoo H, Jeong SH, Kim DS, et al. Longitudinal changes in clinical features, management, and outcomes of idiopathic pulmonary fibrosis: a nationwide cohort study. Ann Am Thorac Soc 2021;18:780-7.
24. Abramson MJ, Murambadoro T, Alif SM, Benke GP, Dharmage SC, Glaspole I, et al. Occupational and environmental risk factors for idiopathic pulmonary fibrosis in Australia: case-control study. Thorax 2020;75:864-9.
25. Richeldi L, du Bois RM, Raghu G, Azuma A, Brown KK, Costabel U, et al. Efficacy and safety of nintedanib in idiopathic pulmonary fibrosis. N Engl J Med 2014;370:2071-82.
26. King TE Jr, Bradford WZ, Castro-Bernardini S, Fagan EA, Glaspole I, Glassberg MK, et al. A phase 3 trial of pirfenidone in patients with idiopathic pulmonary fibrosis. N Engl J Med 2014;370:2083-92.
27. Kreuter M, Ehlers-Tenenbaum S, Palmowski K, Bruhwyler J, Oltmanns U, Muley T, et al. Impact of comorbidities on mortality in patients with idiopathic pulmonary fibrosis. PLoS One 2016;11:e0151425.
28. Brown SW, Dobelle M, Padilla M, Agovino M, Wisnivesky JP, Hashim D, et al. Idiopathic pulmonary fibrosis and lung cancer: a systematic review and meta-analysis. Ann Am Thorac Soc 2019;16:1041-51.
29. Antoniou KM, Tomassetti S, Tsitoura E, Vancheri C. Idiopathic pulmonary fibrosis and lung cancer: a clinical and pathogenesis update. Curr Opin Pulm Med 2015;21:626-33.
30. JafariNezhad A, YektaKooshali MH. Lung cancer in idiopathic pulmonary fibrosis: a systematic review and meta-analysis. PLoS One 2018;13:e0202360.
31. Raghu G, Amatto VC, Behr J, Stowasser S. Comorbidities

in idiopathic pulmonary fibrosis patients: a systematic literature review. Eur Respir J 2015;46:1113-30.
32. Ryerson CJ, Hartman T, Elicker BM, Ley B, Lee JS, Abbritti M, et al. Clinical features and outcomes in combined pulmonary fibrosis and emphysema in idiopathic pulmonary fibrosis. Chest 2013;144:234-40.
33. Bedard Methot D, Leblanc E, Lacasse Y. Meta-analysis of gastroesophageal reflux disease and idiopathic pulmonary fibrosis. Chest 2019;155:33-43.
34. Lee JH, Park CS, Song JW. Obstructive sleep apnea in patients with interstitial lung disease: prevalence and predictive factors. PLoS One 2020;15:e0239963.
35. Douglas WW, Ryu JH, Schroeder DR. Idiopathic pulmonary fibrosis: impact of oxygen and colchicine, prednisone, or no therapy on survival. Am J Respir Crit Care Med 2000;161(4 Pt 1):1172-8.
36. Gribbin J, Hubbard RB, Le Jeune I, Smith CJ, West J, Tata LJ. Incidence and mortality of idiopathic pulmonary fibrosis and sarcoidosis in the UK. Thorax 2006;61:980-5.
37. King TE, Tooze JA, Schwarz MI, Brown KR, Cherniack RM. Predicting survival in idiopathic pulmonary fibrosis: scoring system and survival model. Am J Respir Crit Care Med 2001;164:1171-81.
38. Scott J, Johnston I, Britton J. What causes cryptogenic fibrosing alveolitis? A case-control study of environmental exposure to dust. BMJ 1990;301:1015-7.
39. Mannino DM, Etzel RA, Parrish RG. Pulmonary fibrosis deaths in the United States, 1979-1991: an analysis of multiple-cause mortality data. Am J Respir Crit Care Med 1996;153:1548-52.
40. Raghu G, Freudenberger TD, Yang S, Curtis JR, Spada C, Hayes J, et al. High prevalence of abnormal acid gastro-oesophageal reflux in idiopathic pulmonary fibrosis. Eur Respir J 2006;27:136-42.
41. Nishimura K, Kitaichi M, Izumi T, Nagai S, Kanaoka M, Itoh H. Usual interstitial pneumonia: histologic correlation with high-resolution CT. Radiology 1992;182:337-42.
42. Johkoh T, Muller NL, Cartier Y, Kavanagh PV, Hartman TE, Akira M, et al. Idiopathic interstitial pneumonias: diagnostic accuracy of thin-section CT in 129 patients. Radiology 1999;211:555-60.
43. Raghu G, Lynch D, Godwin JD, Webb R, Colby TV, Leslie KO, et al. Diagnosis of idiopathic pulmonary fibrosis with high-resolution CT in patients with little or no radiological evidence of honeycombing: secondary analysis of a randomised, controlled trial. Lancet Respir Med 2014;2:277-84.
44. Hunninghake GW, Zimmerman MB, Schwartz DA, King TE, Lynch J, Hegele R, et al. Utility of a lung biopsy for the diagnosis of idiopathic pulmonary fibrosis. Am J Respir Crit Care Med 2001;164:193-6.
45. Raghu G, Mageto YN, Lockhart D, Schmidt RA, Wood DE, Godwin JD. The accuracy of the clinical diagnosis of new-onset idiopathic pulmonary fibrosis and other interstitial lung disease: a prospective study. Chest 1999;116:1168-74.
46. Chung JH, Chawla A, Peljto AL, Cool CD, Groshong SD, Talbert JL, et al. CT scan findings of probable usual interstitial pneumonitis have a high predictive value for histologic usual interstitial pneumonitis. Chest 2015;147:450-9.
47. Mayo JR. CT evaluation of diffuse infiltrative lung disease: dose considerations and optimal technique. J Thorac Imaging 2009;24:252-9.
48. Ravaglia C, Bonifazi M, Wells AU, Tomassetti S, Gurioli C, Piciucchi S, et al. Safety and diagnostic yield of transbronchial lung cryobiopsy in diffuse parenchymal lung diseases: a comparative study versus video-assisted thoracoscopic lung biopsy and a systematic review of the literature. Respiration 2016;91:215-27.
49. Tomassetti S, Wells AU, Costabel U, Cavazza A, Colby TV, Rossi G, et al. Bronchoscopic lung cryobiopsy increases diagnostic confidence in the multidisciplinary diagnosis of idiopathic pulmonary fibrosis. Am J Respir Crit Care Med 2016;193:745-52.
50. Noble PW, Albera C, Bradford WZ, Costabel U, Glassberg MK, Kardatzke D, et al. Pirfenidone in patients with idiopathic pulmonary fibrosis (CAPACITY): two randomised trials. Lancet 2011;377:1760-9.
51. Taniguchi H, Ebina M, Kondoh Y, Ogura T, Azuma A, Suga M, et al. Pirfenidone in idiopathic pulmonary fibrosis. Eur Respir J 2010;35:821-9.
52. Azuma A, Nukiwa T, Tsuboi E, Suga M, Abe S, Nakata K, et al. Double-blind, placebo-controlled trial of pirfenidone in patients with idiopathic pulmonary fibrosis. Am J Respir Crit Care Med 2005;171:1040-7.
53. Albera C, Costabel U, Fagan EA, Glassberg MK, Gorina E, Lancaster L, et al. Efficacy of pirfenidone in patients with idiopathic pulmonary fibrosis with more preserved lung function. Eur Respir J 2016;48:843-51.
54. Maher TM, Lancaster LH, Jouneau S, Morrison L, Lederer DJ, Molina-Molina M, et al. Pirfenidone treatment in individuals with idiopathic pulmonary fibrosis: impact of timing of treatment initiation. Ann Am Thorac Soc 2019;16:927-30.
55. Noble PW, Albera C, Bradford WZ, Costabel U, du Bois RM, Fagan EA, et al. Pirfenidone for idiopathic pulmonary fibrosis: analysis of pooled data from three multinational phase 3 trials. Eur Respir J 2016;47:243-53.
56. Zurkova M, Kriegova E, Kolek V, Lostakova V, Sterclova M, Bartos V, et al. Effect of pirfenidone on lung function decline and survival: 5-yr experience from a real-life IPF cohort from the Czech EMPIRE registry. Respir Res 2019;20:16.

57. Kolb M, Richeldi L, Behr J, Maher TM, Tang W, Stowasser S, et al. Nintedanib in patients with idiopathic pulmonary fibrosis and preserved lung volume. Thorax 2017;72:340-6.
58. Richeldi L, Costabel U, Selman M, Kim DS, Hansell DM, Nicholson AG, et al. Efficacy of a tyrosine kinase inhibitor in idiopathic pulmonary fibrosis. N Engl J Med 2011;365:1079-87.
59. Richeldi L, Cottin V, du Bois RM, Selman M, Kimura T, Bailes Z, et al. Nintedanib in patients with idiopathic pulmonary fibrosis: combined evidence from the TOMORROW and INPULSIS trials. Respir Med 2016;113:74-9.
60. Richeldi L, Collard HR, Jones MG. Idiopathic pulmonary fibrosis. Lancet 2017;389:1941-52.
61. Salisbury ML, Wijsenbeek MS. Management of idiopathic pulmonary fibrosis. Clin Chest Med 2021;42:275-85.
62. Jovanovic DM, Sterclova M, Mogulkoc N, Lewandowska K, Muller V, Hajkova M, et al. Comorbidity burden and survival in patients with idiopathic pulmonary fibrosis: the EMPIRE registry study. Respir Res 2022;23:135.
63. Caminati A, Lonati C, Cassandro R, Elia D, Pelosi G, Torre O, et al. Comorbidities in idiopathic pulmonary fibrosis: an underestimated issue. Eur Respir Rev 2019;28:190044.
64. Hubbard R, Venn A, Lewis S, Britton J. Lung cancer and cryptogenic fibrosing alveolitis: a population-based cohort study. Am J Respir Crit Care Med 2000;161:5-8.
65. Torrisi SE, Vancheri A, Pavone M, Sambataro G, Palmucci S, Vancheri C. Comorbidities of IPF: how do they impact on prognosis. Pulm Pharmacol Ther 2018;53:6-11.
66. Song MJ, Kim SY, Park MS, Kang MJ, Lee SH, Park SC. A nationwide population-based study of incidence and mortality of lung cancer in idiopathic pulmonary fibrosis. Sci Rep 2021;11:2596.
67. Tomassetti S, Gurioli C, Ryu JH, Decker PA, Ravaglia C, Tantalocco P, et al. The impact of lung cancer on survival of idiopathic pulmonary fibrosis. Chest 2015;147:157-64.
68. Reck M, Kaiser R, Mellemgaard A, Douillard JY, Orlov S, Krzakowski M, et al. Docetaxel plus nintedanib versus docetaxel plus placebo in patients with previously treated non-small-cell lung cancer (LUME-Lung 1): a phase 3, double-blind, randomised controlled trial. Lancet Oncol 2014;15:143-55.
69. Mediavilla-Varela M, Boateng K, Noyes D, Antonia SJ. The anti-fibrotic agent pirfenidone synergizes with cisplatin in killing tumor cells and cancer-associated fibroblasts. BMC Cancer 2016;16:176.
70. Miura Y, Saito T, Tanaka T, Takoi H, Yatagai Y, Inomata M, et al. Reduced incidence of lung cancer in patients with idiopathic pulmonary fibrosis treated with pirfenidone. Respir Investig 2018;56:72-9.
71. Millan-Billi P, Serra C, Alonso Leon A, Castillo D. Comorbidities, complications and non-pharmacologic treatment in idiopathic pulmonary fibrosis. Med Sci (Basel) 2018;6:59.
72. Cottin V, Selman M, Inoue Y, Wong AW, Corte TJ, Flaherty KR, et al. Syndrome of combined pulmonary fibrosis and emphysema: an official ATS/ERS/JRS/ALAT research statement. Am J Respir Crit Care Med 2022;206:e7-41.
73. Cottin V, Azuma A, Raghu G, Stansen W, Stowasser S, Schlenker-Herceg R, et al. Therapeutic effects of nintedanib are not influenced by emphysema in the INPULSIS trials. Eur Respir J 2019;53:1801655.
74. Lancaster LH, Mason WR, Parnell JA, Rice TW, Loyd JE, Milstone AP, et al. Obstructive sleep apnea is common in idiopathic pulmonary fibrosis. Chest 2009;136:772-8.
75. Mermigkis C, Stagaki E, Tryfon S, Schiza S, Amfilochiou A, Polychronopoulos V, et al. How common is sleep-disordered breathing in patients with idiopathic pulmonary fibrosis? Sleep Breath 2010;14:387-90.
76. Mermigkis C, Bouloukaki I, Schiza SE. Sleep as a new target for improving outcomes in idiopathic pulmonary fibrosis. Chest 2017;152:1327-38.
77. Mermigkis C, Bouloukaki I, Antoniou K, Papadogiannis G, Giannarakis I, Varouchakis G, et al. Obstructive sleep apnea should be treated in patients with idiopathic pulmonary fibrosis. Sleep Breath 2015;19:385-91.
78. Raghu G, Pellegrini CA, Yow E, Flaherty KR, Meyer K, Noth I, et al. Laparoscopic anti-reflux surgery for the treatment of idiopathic pulmonary fibrosis (WRAP-IPF): a multicentre, randomised, controlled phase 2 trial. Lancet Respir Med 2018;6:707-14.
79. Dutta P, Funston W, Mossop H, Ryan V, Jones R, Forbes R, et al. Randomised, double-blind, placebo-controlled pilot trial of omeprazole in idiopathic pulmonary fibrosis. Thorax 2019;74:346-53.
80. Tran T, Assayag D, Ernst P, Suissa S. Effectiveness of proton pump inhibitors in idiopathic pulmonary fibrosis: a population-based cohort study. Chest 2021;159:673-82.
81. Khor YH, Bissell B, Ghazipura M, Herman D, Hon SM, Hossain T, et al. Antacid medication and antireflux surgery in patients with idiopathic pulmonary fibrosis: a systematic review and meta-analysis. Ann Am Thorac Soc 2022;19:833-44.
82. Karkkainen M, Nurmi H, Kettunen HP, Selander T, Purokivi M, Kaarteenaho R. Underlying and immediate causes of death in patients with idiopathic pulmonary fibrosis. BMC Pulm Med 2018;18:69.
83. Nathan SD, Basavaraj A, Reichner C, Shlobin OA, Ahmad S, Kiernan J, et al. Prevalence and impact of coronary artery disease in idiopathic pulmonary fibrosis. Respir Med 2010;104:1035-41.
84. Lee YJ, Choi SM, Lee YJ, Cho YJ, Yoon HI, Lee JH, et al. Clinical impact of depression and anxiety in pa-

tients with idiopathic pulmonary fibrosis. PLoS One 2017;12:e0184300.
85. Glaspole IN, Watson AL, Allan H, Chapman S, Cooper WA, Corte TJ, et al. Determinants and outcomes of prolonged anxiety and depression in idiopathic pulmonary fibrosis. Eur Respir J 2017;50:1700168.
86. Isshiki T, Sakamoto S, Yamasaki A, Shimizu H, Miyoshi S, Nakamura Y, et al. Incidence of acute exacerbation of idiopathic pulmonary fibrosis in patients receiving antifibrotic agents: real-world experience. Respir Med 2021;187:106551.
87. Yoo JW, Kim J, Song JW. Impact of the revised definition on incidence and outcomes of acute exacerbation of idiopathic pulmonary fibrosis. Sci Rep 2022;12:8817.
88. Polke M, Kondoh Y, Wijsenbeek M, Cottin V, Walsh SL, Collard HR, et al. Management of acute exacerbation of idiopathic pulmonary fibrosis in specialised and non-specialised ILD centres around the world. Front Med (Lausanne) 2021;8:699644.
89. Kondoh Y, Taniguchi H, Yokoi T, Nishiyama O, Ohishi T, Kato T, et al. Cyclophosphamide and low-dose prednisolone in idiopathic pulmonary fibrosis and fibrosing nonspecific interstitial pneumonia. Eur Respir J 2005;25:528-33.
90. Horita N, Akahane M, Okada Y, Kobayashi Y, Arai T, Amano I, et al. Tacrolimus and steroid treatment for acute exacerbation of idiopathic pulmonary fibrosis. Intern Med 2011;50:189-95.
91. Oishi K, Azuma A, Abe S, Murata Y, Sakamoto K, Mimura Y, et al. Improved prognostic prediction by combination of early initiation of polymyxin B hemoperfusion with modified gender-age-physiology index in acute exacerbation of idiopathic pulmonary fibrosis. Blood Purif 2022;51:485-91.
92. Petnak T, Lertjitbanjong P, Thongprayoon C, Moua T. Impact of antifibrotic therapy on mortality and acute exacerbation in idiopathic pulmonary fibrosis: a systematic review and meta-analysis. Chest 2021;160:1751-63.
93. Chambers DC, Perch M, Zuckermann A, Cherikh WS, Harhay MO, Hayes D Jr, et al. The International Thoracic Organ Transplant Registry of the International Society for Heart and Lung Transplantation. Thirty-eighth adult lung transplantation report-2021: focus on recipient characteristics. J Heart Lung Transplant 2021;40:1060-72.
94. Jeong YH, Kim DK, Choi S. Current status of lung transplantation in Korea. Curr Chall Thorac Surg 2022;4:4.
95. Leard LE, Holm AM, Valapour M, Glanville AR, Attawar S, Aversa M, et al. Consensus document for the selection of lung transplant candidates: an update from the International Society for Heart and Lung Transplantation. J Heart Lung Transplant 2021;40:1349-79.
96. Kim HK, Lee DY, Paik HC, Mun DS, Bae KM, Han JY, et al. Single lung transplantation in pulmonary fibrosis patients. J Korean Soc Transplant 1999;13:165-9.
97. Jo KW, Hong SB, Kim DK, Jung SH, Kim HR, Choi SH, et al. Long-term outcomes of adult lung transplantation recipients: a single-center experience in South Korea. Tuberc Respir Dis (Seoul) 2019;82:348-56.