scientific reports

Check for updates

OPEN

One-year clinical outcomes of implantable collamer lens implantation for myopic regression after laser vision correction

Ji Youn Choi[1,4], Seung Eun Lee[1], Min Ho Kang[2,3], Dong Hui Lim[4,5], Byoung Woo Ko[1] & Joon Hyun Kim[1]✉

This retrospective, observational case series aimed to evaluate the one-year outcomes of Implantable Collamer Lens (ICL, STAAR Surgical, Nidau, Switzerland) implantation for myopic regression following laser vision correction. We assessed patients who underwent ICL implantation to correct myopic regression after corneal refractive surgery. Visual and refractive outcomes, corneal higher-order aberrations (HOAs), and endothelial cell counts were also evaluated. A total of 66 eyes from 34 patients with spherical equivalent ranging from − 4.50 to − 1.00 diopters (D) were included. At one year, A Snellen uncorrected distance visual acuity (UDVA) of 20/20 or better was achieved in 94% of the eyes, and no loss of corrected distance visual acuity (CDVA) was observed. The efficacy index (postoperative UDVA/preoperative CDVA) and safety index (postoperative CDVA/preoperative CDVA) were 1.08 and 1.09, respectively, and the mean spherical equivalent were − 0.16 ± 0.28 D. Additionally, 98% of eyes achieved spherical equivalent refractions within ± 1.00 D, and all eyes had residual astigmatism within 1.00 D. Keratometry, endothelial cell density, and HOAs exhibited no significant changes ($p > 0.05$). According to our experience, ICL implantation appears to be a safe, effective, and predictable treatment option for correcting myopic regression particularly in cases with insufficient residual stromal thickness after laser vision correction, while maintaining visual quality without increasing corneal HOAs.

Keywords Myopic regression, ICL implantation, Efficacy, Safety, Visual quality

Over the past few decades, corneal refractive procedures, including photorefractive keratectomy (PRK), laser in situ keratomileusis (LASIK), and keratorefractive lenticule extraction (KLEx) have been performed worldwide. These procedures have allowed many individuals to reduce their dependence on glasses, significantly enhancing their quality of life and daily activities[1,2]. Laser vision correction (LVC) surgery has consistently demonstrated high efficacy and safety in terms of clinical outcomes[3–5],but myopic regression, which may occur over time following surgery, can cause inconvenience in patients by necessitating the use of glasses. This regression results in the corneal tendency to return to its preoperative state, particularly in patients with high myopia[6,7]. In such cases, retreatment options, such as laser enhancement or implantable collamer lens (ICL) implantation, may be considered. However, laser enhancement poses potential risks, including postoperative corneal complications such as corneal ectasia and epithelial ingrowth, and is not suitable for eyes with insufficient residual corneal thickness[8]. Additionally, postoperative pain following LVC may deter patients from undergoing repeated laser ablation surgery[9,10]. ICL implantation offers a safer and structurally conservative alternative, for patients with limited residual stromal thickness. Several studies have reported the clinical outcomes of ICL implantation for myopic regression following previous LVC[11,12].Additionally, a few case reports have documented the use of ICL to correct residual hyperopia, reporting safe and effective outcomes[13,14]. However, long-term outcomes in larger cohorts remain limited, making it difficult to draw generalized conclusions.

[1]Apgujeong Eye Clinic, Seocho-gu, Seoul 06011, Korea. [2]Department of Ophthalmology, Hanyang University College of Medicine, Seoul 04763, Korea. [3]Department of Ophthalmology, Hanyang University Guri Hospital, Guri 11923, Korea. [4]Department of Ophthalmology, Samsung Medical Center School of Medicine, Sungkyunkwan University, Seoul 06351, Korea. [5]Samsung Advanced Institute for Health Sciences and Technology (SAIHST), Sungkyunkwan University, Seoul 06355, Korea. ✉email: joshua0219@hotmail.com

This study aimed to evaluate the one-year clinical outcomes of ICL implantation, including corneal higher-order aberrations (HOAs), in a substantial cohort of eyes with myopic regression following prior laser correction procedures.

Results

Patient characteristics

A total of 66 eyes of 34 patients were included in this study. Of these, 44 eyes of 23 patients had a history of PRK, whereas 22 eyes of 11 patients had undergone LASIK. The mean interval since prior LVC was 12.61 ± 3.46 years. The mean preoperative spherical equivalent (SE) was − 2.41 ± 0.74 diopters (D), and the mean central corneal thickness was 454.14 ± 42.17 µm.

Preoperative patient demographics and analyses based on surgery type are summarized in Table 1. The PRK group showed significantly thinner central corneal thickness (443.59 ± 42.03) and lower manifest refractive cylinder values (–0.33 ± 0.30) compared with the LASIK group (475.23 ± 33.70 and − 0.70 ± 0.42, respectively) (both, $p < 0.05$). No significant differences were observed between the two groups in terms of mean keratometry, endothelial cell count, or SE. Mean keratometry (38.67 ± 2.09 in the PRK group vs. 38.75 ± 1.19 in the LASIK group), endothelial cell count (2851.34 ± 356.49 vs. 2797.68 ± 281.30), and spherical equivalent (–2.34 ± 0.67 vs. − 2.56 ± 0.86) did not differ significantly between the two groups.

Visual outcomes

At the one-year follow-up, an uncorrected distance visual acuity (UDVA) of 20/20 or better was achieved in 94% of the eyes, while a preoperative corrected distance visual acuity (CDVA) of 20/20 or better was obtained in 98% of the eyes on the Snellen scale (Figure. 1A). No preoperative CDVA values exceeding 20/20 were documented, accounting for 0.0% of this category. The calculated efficacy index was 1.08.

Safety

CDVA remained stable in 89% of the eyes, whereas 11% of the eyes showed an improvement of one or more lines (Figure. 1B). Importantly, none of the eyes experienced loss of one or more CDVA lines. The calculated safety index is 1.09. Within the first year of follow-up, two eyes required ICL exchange to a higher-powered due to postoperative under-correction. These eyes exhibited a larger prediction error at 3 months after the primary implantation (SE: − 0.68 D and − 1.13 D, respectively), accompanied by suboptimal UDVA, both of which improved following lens exchange. Accordingly, the refractive predictability shown in Fig. 1 and the reported mean SE represent the final visual and refractive outcomes after ICL exchange, not the results of the initial lens calculation. No significant postoperative complications, such as ICL-related cataracts, elevated intraocular pressure, or endophthalmitis were observed throughout the follow-up examinations.

Refractive outcomes

The predictive ability of the procedure was evaluated by comparing the attempted and achieved SE refractions using a scatter plot (Figure. 1C). The analysis revealed a slope of 0.92 and a coefficient of determination (R^2) of 0.98. In terms of refractive accuracy, 88% of eyes achieved SE refractions within ± 0.50 D of the target, and 98% were within ± 1.00 D (Figure. 1D). One year postoperatively, 91% and 100% of eyes had residual astigmatism within 0.50 D and 1.00 D respectively, compared to 69% and 97% of eyes preoperatively (Figure. 1E). All cases

Types of previous surgery	Total	PRK	LASIK	*p*-value
Eyes (patients)	66 (34)	44 (23)	22 (11)	
Age (years)	34.77 ± 3.61 [28, 40]	33.89 ± 3.44 [28, 40]	36.55 ± 3.26 [30, 40]	0.004*
Sex (male/female) [%]	23 [35]/43 [65]	17 [39]/27 [61]	6 [27]/16 [72]	0.361
Time interval after previous surgery (years)	12.61 ± 3.46 [6, 20]	12.18 ± 3.32 [8, 20]	13.46 ± 3.58 [6, 18]	0.079
Residual corneal thickness (µm)	454.14 ± 42.17 [364, 566]	443.59 ± 42.03 [364, 566]	475.23 ± 33.70 [427, 545]	0.002*
Mean keratometry (D)	38.70 ± 1.84 [34.38, 42.63]	38.67 ± 2.09 [34.38, 42.63]	38.75 ± 1.19 [36.50, 40.63]	0.847
Endothelial cell count (/mm^2)	2833.45 ± 334.27 [1921, 3359]	2851.34 ± 356.49 [1921, 3359]	2797.68 ± 281.30 [2289, 3316]	0.418
Anterior chamber depth (mm)	3.13 ± 0.21 [2.73, 3.50]	3.12 ± 0.23 [2.73, 3.50]	3.15 ± 0.17 [2.80, 3.42]	0.683
Manifest sphere (D)	−2.18 ± 0.77 [− 4.25, − 0.50]	−2.17 ± 0.68 [− 3.50, − 0.75]	−2.20 ± 0.93 [− 4.25, − 0.50]	0.882
Manifest cylinder (D)	−0.45 ± 0.37 [− 1.50, 0.00]	−0.33 ± 0.30 [− 1.00, 0.00]	−0.70 ± 0.42 [− 1.50, 0.00]	< 0.001*
Manifest spherical equivalent (D)	−2.41 ± 0.74 [− 4.50, − 1.00]	−2.34 ± 0.67 [− 3.50, − 1.13]	−2.56 ± 0.86 [− 4.50, − 1.00]	0.311

Table 1. Baseline characteristics of eyes according to previous surgery types. All values are expressed as mean ± standard deviation [range]. D, diopters; LASIK, laser in situ keratomileusis; PRK, photorefractive keratectomy; asterisks (*) indicate statistically significant differences ($p < 0.05$).

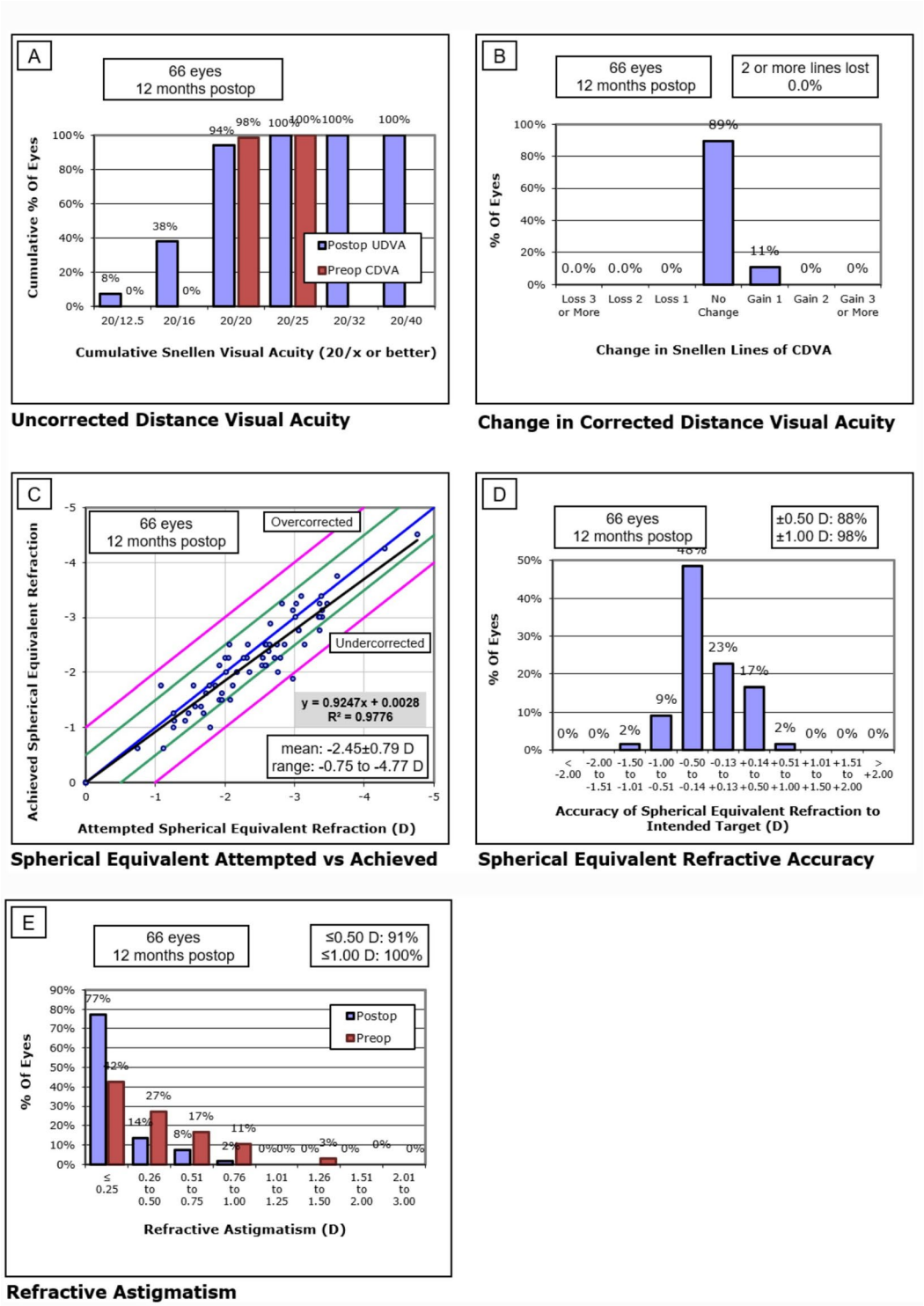

Fig. 1. Standard graphs for reporting refractive outcomes 1 year after Implantable Collamer Lens implantation in eyes with myopic regression after previous laser vision correction surgery. (**A**) Preoperative uncorrected distance visual acuity and postoperative uncorrected distance visual acuity. (**B**) Change in Snellen lines of corrected distance visual acuity after the procedure. (**C**) Attempts in relation to achieved spherical equivalent refraction. (**D**) Accuracy of postoperative spherical equivalent. (**E**) Preoperative and postoperative residual astigmatism. CDVA = corrected distance visual acuity; D = diopters; Postop = postoperative; Preop = preoperative; SD = standard deviation; UDVA = uncorrected distance visual acuity.

Characteristics	Mean ± SD		*p*-value*
	Preoperative	Year 1	
Central corneal thickness (μm)	454.14 ± 42.17 [364, 566]	455.98 ± 41.18 [370, 567]	0.092
Mean keratometry (D)	38.70 ± 1.84 [34.38, 42.63]	38.74 ± 1.92 [34.50, 42.88]	0.219
Endothelial cell count (/mm^2)	2833.45 ± 334.27 [1921, 3359]	2783.52 ± 323.93 [1948, 3952]	0.060
Corneal HOAs (n = 49, μm)			
Total HOA	1.03 ± 0.44	1.04 ± 0.45	0.257
Spherical aberration	0.53 ± 0.21	0.52 ± 0.20	0.335
Total coma	0.69 ± 0.40	0.74 ± 0.44	0.184
Total trefoil	0.19 ± 0.15	0.23 ± 0.21	0.079

Table 2. Preoperative and one-year postoperative parameters measured in the eyes. All values are expressed as mean ± standard deviation [range]. D, diopters; HOAs: higher-order aberrations; asterisks (*) indicate statistically significant differences ($p < 0.05$).

were implanted with non-toric ICL, and the refractive astigmatism correction is presumed to be the result of surgically induced astigmatism.

Corneal changes and higher-order aberrations

Table 2 shows the changes in corneal characteristics, including HOAs, following ICL implantation. As some patients missed Scheimpflug-based Pentacam examinations during follow-up, the analysis of corneal HOAs included only 49 eyes from 25 patients. To assess potential selection bias due to missing HOAs data, baseline characteristics were compared between eyes included in the analysis ($n = 49$) and those excluded due to missing examinations ($n = 17$). There were no significant differences between the two groups in age, mean keratometry, preoperative UDVA, CDVA, and manifest SE. At one year postoperatively, there were no significant changes in mean keratometry, pachymetry, or endothelial cell count compared to the preoperative values (Table 2). Similarly, no significant differences were observed between the preoperative and postoperative groups in terms of total HOA, spherical aberration, total coma, or total trefoil.

Discussions

Few studies have evaluated the outcomes of ICL implantation in patients with LVC history. This study builds upon these findings and demonstrates that ICL implantation is a safe and effective option for treating myopic regression following primary LVC.

Chung et al. reported the 3-month outcomes of ICL implantation in 30 eyes that had previously undergone PRK or LASIK[12]. In comparison, our study presents one-year results from a larger cohort. A UDVA of 20/20 or better was achieved in 94% of the eyes in our study, compared to 83% in the study by Chung et al. CDVA was maintained or improved in 100% of eyes in our study, whereas it was 97% in another study. SE refractions within ± 1.00 D of the target were achieved in 98% of the eyes in our study, compared to 100% in the other. Residual astigmatism within ± 1.00 D was reported in 100% of the eyes in our study, versus 97% in the other. The efficacy and safety indices were 1.08 and 1.09 respectively, further supporting the positive outcomes of ICL implantation in post-LVC eyes, especially for those unsuitable for laser enhancement due to insufficient residual stromal tissue.

In addition to prior studies focused on phakic eyes, Alfonso et al. evaluated ICL implantation in pseudophakic eyes with various previous corneal surgeries, including LASIK, PRK, radial keratectomy, intrastromal corneal ring segments implantation, and keratoplasty[15]. The subgroup with prior excimer laser surgery in their study achieved high levels of predictability and showed safety indices comparable to our findings. Although their study involved pseudophakic eyes, the consistent outcomes across surgically altered corneas highlight the versatility of ICL implantation. These results align with our findings and further support its applicability in both phakic and pseudophakic eyes with previous corneal procedures.

Importantly, this study showed no significant postoperative changes in mean keratometry or HOAs. Unlike laser enhancement procedures that tend to flatten the cornea and induce oblate changes, ICL implantation preserves the prolate shape of the cornea[16]. This offers an advantage in maintaining corneal biomechanical stability and minimizing HOAs[17–20]. The study findings suggest that ICL implantation for eyes with previous LVC may be a viable option, without increasing HOAs. Furthermore, none of the eyes showed elevated intraocular pressure during the follow-up examinations, nor was there any significant postoperative decrease in endothelial cell counts.

A previous study by Chen et al. reported outcomes from 19 eyes over a mean follow-up of 39 months[11]. A mild myopic shift was observed after five years, which may be attributable to axial length elongation, age-related changes in the crystalline lens, or gradual corneal steepening from the early postoperative period to the final follow-up[11]. In contrast, our study had a relatively shorter follow-up and lacked data such as axial length measurements, limiting the ability to evaluate long-term refractive changes.

This study has certain limitations. First, it was retrospective. Second, although the sample size was larger than that of previous studies on ICL implantation after LVC, it remained relatively small. Third, the absence of a comparison group, consisting of patients who underwent laser enhancement, limited the ability to interpret outcomes. Fourth, as this was not a longitudinal study, refractive stability from the early postoperative period to the one-year follow-up could not be assessed.

In conclusion, ICL implantation in eyes with myopic regression after LVC demonstrated safe and effective results one year postoperatively, maintaining visual quality without increasing corneal HOAs. These findings suggest that ICL implantation may be considered an alternative treatment option, particularly in cases where further laser enhancement is limited by insufficient residual stromal thickness. Further long-term studies with larger cohorts are required to validate and expand upon these findings.

Methods

Participants

This retrospective observational study adhered to the guidelines outlined in the Declaration of Helsinki and Good Clinical Practice. Ethical approval was obtained from the Institutional Review Board of the Hanyang University Guri Hospital (IRB No. 2024-12-032-002). Given the retrospective nature of this study, the requirement for informed consent was waived. All patients underwent ICL implantation between July 2019 and August 2023 following a comprehensive ocular examination and detailed preoperative counseling with explanation of possible enhancement options. This study included 66 eyes from 34 patients who met the following inclusion criteria: CDVA of 20/30 or better; stable manifest refraction values for at least one year; no significant corneal abnormalities such as ectasia or severe dry eye; no history of ocular trauma; no preexisting ocular conditions such as retinal disorders, cataracts, glaucoma; and an endothelial cell density of > 2000 cells/mm^2. Patients whose predicted residual stromal thickness was less than 300 μm after laser enhancement were primarily included, to avoid the increased risk of postoperative ectasia after retreatment.

Ocular measurements

Ocular assessments included manifest refraction, UDVA, CDVA, slit-lamp examination, autorefraction, keratometry (KR-800 Auto Ref/Keratometer, Topcon, Tokyo, Japan), intraocular pressure measurement (CT-80; Topcon, Tokyo, Japan), fundoscopy (VISUCAM 524, Carl Zeiss Meditec, Jena, Germany), specular microscopy (SP-1P, Topcon, Tokyo, Japan), anterior chamber depth, central corneal thickness, corneal HOAs, and corneal topography (Pentacam, OCULUS Optikgeräte GmbH, Wetzlar, Germany).

All patients were evaluated preoperatively, and one year postoperatively. The efficacy index was calculated as the ratio of postoperative UDVA to preoperative CDVA. The safety index was estimated as the ratio of the postoperative CDVA to the preoperative CDVA.

Surgical procedure

On the day of surgery, 0.5% phenylephrine and 0.5% tropicamide (Mydrin-P; Santen Pharmaceutical, Osaka, Japan) were administered for mydriasis. Under anesthesia with 0.5% proparacaine hydrochloride ophthalmic solution (Alcaine; Alcon Laboratories, Inc., Fort Worth, TX, USA) supplemented with 0.5% intracameral lidocaine, the angle-to-angle distance was measured using a caliper to validate ICL size. A 3.0-mm incision was made superiorly for eyes with with-the-rule astigmatism and temporally for eyes with against-the-rule astigmatism or without any astigmatism, to minimize it. An ophthalmic viscosurgical device (1% sodium hyaluronate; Healon, Johnson & Johnson Vision, Jacksonville, FL, USA) was injected into the anterior chamber and a VICM5 ICL model (STAAR Surgical, Inc., Monrovia, CA) was inserted into the posterior chamber using an injector cartridge, followed by irrigation with a balanced salt solution. All surgeries were completed without any intraoperative complications. Patients were prescribed 1% prednisolone (Pred Forte, Allergan, Irvine, CA, USA) and 0.5% moxifloxacin (Vigamox, Alcon Laboratories, Inc., Fort Worth, TX, USA) four times daily for two weeks, followed by 0.1% fluorometholone (Fluorometholone, Daewoong Pharmaceutical, Seoul, South Korea) four times daily for another two weeks. The power and size of the implanted ICL were determined using a modified vertex formula provided by STAAR Surgical, targeting emmetropia. The entire list of 66 eyes can be found as Supplementary Table S1.

Statistical analysis

Data were organized in a spreadsheet, and the normality of distributions was assessed using the Kolmogorov–Smirnov test. Depending on data distribution, preoperative and postoperative values were compared using paired t-tests or Wilcoxon signed-rank tests. Independent *t*-tests or Mann–Whitney U tests were used for comparisons between two groups. Categorical variables were analyzed using the chi-square test. All statistical analyses were conducted using SPSS for Windows (IBM Corp., Armonk, NY, USA), and statistical significance was set at $p < 0.05$.

Data availability

The data presented in the study are available on request from the corresponding author.

Received: 24 June 2025; Accepted: 29 June 2026
Published online: 01 July 2026

References

1. Ang, M. et al. Refractive surgery beyond 2020. *Eye (Lond)* **35**, 362–382 (2021).

2. Sugar, A., Hood, C. T. & Mian, S. I. Patient-reported outcomes following LASIK: Quality of life in the PROWL studies. *JAMA* **317**, 204–205 (2017).
3. Wen, D. et al. Postoperative efficacy, predictability, safety, and visual quality of laser corneal refractive surgery: A network meta-analysis. *Am. J. Ophthalmol.* **178**, 65–78 (2017).
4. Reinstein, D. Z. et al. Long-term visual and refractive outcomes after LASIK for high myopia and astigmatism from −8.00 to −14.25 D. *J. Refract. Surg.* **32**, 290–297 (2016).
5. Reinstein, D. Z. et al. Small incision lenticule extraction (SMILE) for the correction of high myopia with astigmatism. *J. Refract. Surg.* **38**, 262–271 (2022).
6. Chayet, A. S. et al. Regression and its mechanisms after laser in situ keratomileusis in moderate and high myopia. *Ophthalmology* **105**, 1194–1199 (1998).
7. Güell, J. L. & Muller, A. Laser in situ keratomileusis (LASIK) for myopia from −7 to −18 diopters. *J. Refract. Surg.* **12**, 222–228 (1996).
8. Bower, K. S. & Woreta, F. Update on contraindications for laser-assisted in situ keratomileusis and photorefractive keratectomy. *Curr. Opin. Ophthalmol.* **25**, 251–257 (2014).
9. Betz, J. et al. Ocular pain after refractive surgery: Interim analysis of frequency and risk factors. *Ophthalmology* **130**, 692–701 (2023).
10. Sobas, E. M., Videla, S., Maldonado, M. J. & Pastor, J. C. Ocular pain and discomfort after advanced surface ablation: An ignored complaint. *Clin. Ophthalmol.* **9**, 1625–1632 (2015).
11. Chen, X. et al. Implantable collamer lens for residual refractive error after corneal refractive surgery. *Int. J. Ophthalmol.* **9**, 1421–1426 (2016).
12. Chung, B. et al. 3-month surgical outcomes of implantable collamer lens implantation for myopic regression after laser vision correction surgeries: A retrospective case series. *BMC Ophthalmol.* **21**, 397 (2021).
13. Srinivasan, S., Drake, A. & Herzig, S. Early experience with implantable collamer lens in the management of hyperopia after radial keratotomy. *Cornea* **27**, 302–304 (2008).
14. Kamiya, K., Shimizu, K. & Komatsu, M. Implantable collamer lens implantation and limbal relaxing incisions for the correction of hyperopic astigmatism after laser in situ keratomileusis. *Cornea* **29**, 99–101 (2010).
15. Alfonso, J. F. et al. Implantable Collamer Lens® for management of pseudophakic ametropia in eyes with a spectrum of previous corneal surgery. *J. Refract. Surg.* **34**, 654–663 (2018).
16. Hashemian, S. J. et al. Ocular higher-order aberrations changes after implantable collamer lens implantation for high myopic astigmatism. *J. Curr. Ophthalmol.* **30**, 136–141 (2018).
17. Oshika, T. et al. Comparison of corneal wavefront aberrations after photorefractive keratectomy and laser in situ keratomileusis. *Am. J. Ophthalmol.* **127**, 1–7 (1999).
18. Sekundo, W. et al. One-year refractive results, contrast sensitivity, high-order aberrations and complications after myopic small-incision lenticule extraction (ReLEx SMILE). *Graefes Arch. Clin. Exp. Ophthalmol.* **252**, 837–843 (2014).
19. Zhou, C. et al. Comparison of visual quality after SMILE correction of low-to-moderate myopia in different optical zones. *Int. Ophthalmol.* **43**, 3623–3632 (2023).
20. Seiler, T., Mrochen, M. & Kaemmerer, M. Operative correction of ocular aberrations to improve visual acuity. *J. Refract. Surg.* **16**, S619–S622 (2000).

Author contributions

Conceptualization: Kim JH, Ko BW. Methodology: Kim JH, Ko BW. Validation: Kim JH, Ko BW, Kang MH, Lim DH. Formal analysis: Choi JY. Investigation: Choi JY, Lee SE. Data curation: Choi JY, Lee SE. Writing – original draft: Choi JY. Writing – review and editing: Kim JH, Ko BW, Kang MH, Lim DH. Visualization: Choi JY. Supervision: Kim JH. All authors have read and agreed to the published version of the manuscript.

Declarations

Competing interests

The authors declare no competing interests.

Additional information

Supplementary Information The online version contains supplementary material available at https://doi.org/10.1038/s41598-026-60431-y.

Correspondence and requests for materials should be addressed to J.H.K.

Reprints and permissions information is available at www.nature.com/reprints.

Publisher's note Springer Nature remains neutral with regard to jurisdictional claims in published maps and institutional affiliations.

Open Access This article is licensed under a Creative Commons Attribution-NonCommercial-NoDerivatives 4.0 International License, which permits any non-commercial use, sharing, distribution and reproduction in any medium or format, as long as you give appropriate credit to the original author(s) and the source, provide a link to the Creative Commons licence, and indicate if you modified the licensed material. You do not have permission under this licence to share adapted material derived from this article or parts of it. The images or other third party material in this article are included in the article's Creative Commons licence, unless indicated otherwise in a credit line to the material. If material is not included in the article's Creative Commons licence and your intended use is not permitted by statutory regulation or exceeds the permitted use, you will need to obtain permission directly from the copyright holder. To view a copy of this licence, visit http://creativecommons.org/licenses/by-nc-nd/4.0/.

© The Author(s) 2026